



Official reprint from UpToDate®

www.uptodate.com ©2020 UpToDate, Inc. and/or its affiliates. All Rights Reserved.

Wolters Kluwer

Cervical lymphadenitis in children: Diagnostic approach and initial management

Author: C Mary Healy, MD**Section Editors:** Jan E Drutz, MD, Glenn C Isaacson, MD, FAAP, Morven S Edwards, MD**Deputy Editor:** Mary M Torchia, MDAll topics are updated as new evidence becomes available and our [peer review process](#) is complete.**Literature review current through:** May 2020. | **This topic last updated:** Apr 26, 2018.

INTRODUCTION

The evaluation and initial treatment of cervical lymphadenitis in children will be reviewed here. The pathogenesis, etiology, and clinical manifestations of cervical lymphadenitis and other causes of peripheral lymphadenopathy in children are discussed separately. (See "[Cervical lymphadenitis in children: Etiology and clinical manifestations](#)" and "[Peripheral lymphadenopathy in children: Etiology](#)" and "[Peripheral lymphadenopathy in children: Evaluation and diagnostic approach](#)".)

DEFINITIONS

- Cervical lymphadenopathy – Enlarged lymph node(s) of the neck, including preauricular, parotid, jugulodigastric, submental, submandibular, posterior cervical, superficial cervical, deep cervical, occipital, and posterior auricular (mastoid) ([figure 1](#)); lymphadenopathy encompasses both inflamed and noninflamed lymph nodes.
- Cervical lymphadenitis – Enlarged, inflamed, and tender lymph node(s) of the neck; although strictly speaking, "lymphadenitis" refers to inflamed lymph nodes, the terms "lymphadenitis" and "lymphadenopathy" often are used interchangeably.
- Acute lymphadenitis – Develops over a few days (but may persist for weeks to months).
- Subacute/chronic lymphadenitis – Develops over weeks to months.
- Generalized lymphadenopathy – Enlargement of two or more noncontiguous lymph node regions (eg, cervical and axillary) and is the result of systemic disease. (See "[Peripheral lymphadenopathy in children: Etiology](#)", section on 'Generalized lymphadenopathy'.)

CAUSES

There are numerous infectious and noninfectious causes of enlarged cervical lymph nodes in children ([table 1](#) and [table 2](#)). (See ["Cervical lymphadenitis in children: Etiology and clinical manifestations"](#).)

DIAGNOSTIC APPROACH

Overview — The evaluation of children with cervical lymphadenitis includes a thorough history and physical examination ([table 3](#)) [1]. The goal of the evaluation is to determine the underlying cause, which affects initial management.

The initial laboratory evaluation and management depend upon the findings from the history and examination, and may range from observation and reassurance (for well-appearing children with acute bilateral cervical lymphadenitis that is only slightly enlarged and minimally tender) to comprehensive diagnostic testing and aggressive medical and surgical therapy (for ill-appearing children or those with suspected malignancy or mycobacterial disease). In difficult cases, consultation with a specialist in pediatric infectious diseases can help to direct the evaluation and management.

Unless there are compelling associated symptoms suggestive of noninfectious causes ([table 2](#)), we generally focus the initial evaluation on infectious causes of cervical lymphadenitis because infectious causes are more common and more frequently associated with tenderness and inflammation than noninfectious causes.

The infectious causes of cervical lymphadenitis in children vary depending upon whether the adenitis is acute or subacute/chronic and bilateral or unilateral, although there is some overlap ([table 1](#)). We use this categorization in conjunction with the findings from the history and examination to guide the initial laboratory evaluation and management. (See ['Initial laboratory evaluation and management'](#) below.)

Additional testing depends upon the results of the initial evaluation and the clinical course, including the response to antimicrobial therapy if it is initiated. (See ['Additional evaluation for persistence or uncertain etiology'](#) below.)

The pace of the diagnostic evaluation is dictated by how ill the patient appears. As an example, early excisional biopsy is indicated for children with features suggestive of malignancy or nontuberculous mycobacterial infection. (See ['Suspected malignancy'](#) below and ['Suspected NTM'](#) below and ['Additional evaluation for persistence or uncertain etiology'](#) below.)

History — Important aspects of the history in a child with cervical lymphadenitis include [1]:

- Duration and laterality of enlargement and change in size over time
- Associated symptoms, particularly fever; constitutional symptoms (weight loss, fatigue, malaise); conjunctivitis; pharyngitis; nasal, aural, or sinus obstruction without discharge; dental problems or mouth sores; cough; arthralgia; skin lesions or trauma

- Immunization status (diphtheria, measles, mumps, rubella)
- Exposures:
 - Ill contacts (viral respiratory infections, cytomegalovirus [CMV], Epstein-Barr virus [EBV], *Streptococcus pyogenes* [group A *Streptococcus*, GAS], tuberculosis)
 - Ingestion of unpasteurized animal milk (brucellosis, *Mycobacterium bovis*) or undercooked meats (toxoplasmosis)
 - Animal exposures (cat scratch disease, toxoplasmosis [cats], brucellosis [especially goats], tularemia [especially rabbits], bubonic plague [especially prairie dogs])
 - Flea or tick bites (bubonic plague, tularemia)
 - Medications (eg, [phenytoin](#), [carbamazepine](#))
 - Geographic location and travel within the United States ([tularemia](#), [bubonic plague](#), [tuberculosis](#)) and internationally ([bubonic plague](#), tuberculosis ([figure 2](#)))

Physical examination — A comprehensive physical examination should be performed to look for signs of systemic disease or infection [1]. Special attention should be given to the lymphatic system, conjunctivae, oral cavity, and skin.

- Lymphatic system – Examination of the lymphatic system includes the liver, spleen, and cervical and noncervical lymph nodes.

Hepatosplenomegaly with generalized adenitis may indicate systemic infection (eg EBV, CMV, HIV, histoplasmosis, tuberculosis, syphilis) or noninfectious etiology (eg, malignancy, collagen vascular disease ([table 2](#))).

Assessment of the lymph nodes should include the number, location ([figure 1](#)), size, shape, consistency, tenderness, mobility, and color of overlying skin.

- "Reactive" lymph nodes usually feel soft and are discrete, mobile, and minimally tender; they are often referred to as "shotty" (ie, small and round, like shotgun pellets).
- Infected lymph nodes are usually isolated, asymmetric, tender, warm, and erythematous; they may be fluctuant; they are less mobile and discrete than reactive lymph nodes.
- Malignant lymph nodes often are hard, fixed, or matted to the underlying structures; they usually are nontender.
- Eyes – Conjunctival injection may indicate Parinaud oculoglandular syndrome ([picture 1](#)) (associated with cat scratch disease or tularemia), adenovirus (eg, pharyngoconjunctival fever), or Kawasaki disease ([picture 2](#)). (See "[Microbiology, epidemiology, clinical manifestations, and diagnosis of cat scratch disease](#)" and "[Kawasaki disease: Clinical features and diagnosis](#)".)

- Oral cavity – The oral cavity should be examined for periodontal disease, ulcers ([picture 3A-B](#)), herpes simplex virus (HSV) gingivostomatitis ([picture 4](#)), or pharyngitis.
- Skin – A generalized rash may suggest a nonspecific viral illness (eg, roseola, adenovirus, EBV, measles, rubella, parvovirus B19), Kawasaki disease, juvenile idiopathic arthritis, systemic lupus erythematosus, Langerhans cell histiocytosis, hemophagocytic lymphohistiocytosis.

A localized skin lesion may indicate a more specific etiology:

- Cat scratch disease ([picture 5A-B](#)) (see "[Microbiology, epidemiology, clinical manifestations, and diagnosis of cat scratch disease](#)")
- Tularemia ([picture 6](#)) (see "[Tularemia: Clinical manifestations, diagnosis, treatment, and prevention](#)")
- *Staphylococcus aureus* or GAS (see "[Cellulitis and skin abscess: Clinical manifestations and diagnosis](#)")
- HSV ([picture 7A-B](#)) (see "[Herpetic gingivostomatitis in young children](#)")

Less common infections in which a papular or pustular lesion is suggestive of an inoculation site include [2]:

- Nocardia (see "[Clinical manifestations and diagnosis of nocardiosis](#)")
- Actinomycosis (see "[Cervicofacial actinomycosis](#)")
- Sporotrichosis ([picture 8](#)) (see "[Clinical features and diagnosis of sporotrichosis](#)")
- *Yersinia pestis* (see "[Clinical manifestations, diagnosis, and treatment of plague \(Yersinia pestis infection\)](#)")
- Cutaneous diphtheria

Indications for admission — Potential indications for hospital admission in children with cervical lymphadenitis include:

- Need for parenteral antimicrobial therapy:
 - Acute unilateral cervical lymphadenitis with severe symptoms (eg, ill-appearing, fever, fluctuant node, concomitant cellulitis) (see '[Severe symptoms](#)' below)
 - Acute unilateral cervical lymphadenitis with moderate symptoms (eg, fever, nonfluctuant node) that do not respond to or worsen with oral antimicrobial therapy (see '[Moderate symptoms](#)' below)
- Consideration of Kawasaki disease (see "[Kawasaki disease: Clinical features and diagnosis](#)", [section on 'Clinical manifestations'](#))
- Need for incision and drainage (see '[Moderate symptoms](#)' below and '[Severe symptoms](#)' below)

INITIAL LABORATORY EVALUATION AND MANAGEMENT

Acute bilateral — Viral upper respiratory infection (URI) is the most common cause of acute bilateral cervical lymphadenitis ([table 4](#)) [1]. The initial evaluation and management depend upon the child's clinical status and the course of the lymphadenitis. Although viral URI is the most common cause, evaluation may be necessary to identify causes that require specific therapy (eg, group A *Streptococcus* [GAS]).

Mild illness — Children with acute bilateral cervical lymph nodes that are slightly enlarged, minimally tender, and mobile and who are only mildly ill (ie, well-appearing, absent or low-grade fever, nonprogressive symptoms), generally do not require laboratory testing.

However, testing for GAS is indicated in children with acute bilateral cervical lymphadenitis and exudative pharyngitis. Testing for *Arcanobacterium haemolyticum* may be warranted in adolescents with exudative pharyngitis. Testing for Epstein-Barr virus (EBV) may be warranted if the rapid test for GAS is negative or if the child has generalized lymphadenopathy and/or hepatosplenomegaly. (See "[Clinical manifestations and treatment of Epstein-Barr virus infection](#)", section on 'Primary infection' and "[Group A streptococcal tonsillopharyngitis in children and adolescents: Clinical features and diagnosis](#)", section on 'Diagnosis'.)

Specific treatment usually is not necessary, unless the child has GAS or *A. haemolyticum*. The lymph nodes should be monitored with serial examinations every few weeks until they regress. Follow-up should occur earlier than scheduled if the child develops new or worsening symptoms. (See '[Severe, progressive, or persistent adenitis](#)' below.)

Severe, progressive, or persistent adenitis — For children with acute bilateral cervical lymphadenitis who are ill-appearing, febrile, or have progressive or persistent symptoms (ie, for longer than six to eight weeks without diminishing in size), we suggest the following evaluation:

- Complete blood count (CBC) with differential
- Erythrocyte sedimentation rate (ESR) and/or C-reactive protein (CRP)
- Hepatic profile (looking for evidence of systemic involvement, but not necessarily for a specific pathogen)
- Blood culture
- [Tuberculin skin test](#) (TST) or interferon-gamma release assay (IGRA)
- EBV, cytomegalovirus (CMV), HIV serology; EBV serology is preferred to a monospot test because the monospot may be falsely negative in children
- Other serologic testing (eg, *Toxoplasma gondii*, syphilis, or brucellosis) as indicated by the history and examination

Although some of the infections identified with these tests more commonly cause subacute/chronic cervical lymphadenitis or generalized lymphadenopathy, it is important to consider them in children who are severely ill

or have progressive/persistent cervical lymphadenitis, especially if the infection requires specific therapy (eg, tuberculosis, HIV, syphilis, brucellosis).

The CBC, ESR (and/or CRP), and hepatic profile are nonspecific tests that may provide information about inflammation, bone marrow suppression or infiltration, and systemic involvement. Abnormal results may prompt additional evaluation (eg, bone marrow biopsy in children with peripheral cytopenias or blasts). The remainder of the tests may help to establish an etiology and the need for specific therapy.

Additional testing may be necessary if the child remains ill and the etiology remains uncertain. (See ['Additional evaluation for persistence or uncertain etiology'](#) below.)

The management of children with severe, progressive, or persistent cervical lymphadenitis depends upon the etiology. As examples:

- (See ["Clinical manifestations and treatment of Epstein-Barr virus infection", section on 'Treatment'.](#))
- (See ["Overview of cytomegalovirus infections in children", section on 'Treatment'.](#))
- (See ["Brucellosis: Treatment and prevention", section on 'Treatment'.](#))

Acute unilateral — Acute unilateral cervical lymphadenitis in children usually is caused by *S. aureus*, GAS, or oral anaerobes (in children with poor oral hygiene or periodontal disease) ([table 5](#)) [1,3]. (See ["Cervical lymphadenitis in children: Etiology and clinical manifestations", section on 'Acute unilateral'.](#))

The initial evaluation and management depend upon the severity of symptoms.

Minimal symptoms — Children with acute unilateral cervical lymphadenitis who are well-appearing and whose lymph node is only slightly enlarged and minimally tender usually do not require laboratory testing.

The lymph node should be monitored with serial examinations every few weeks until regression. Follow-up should occur earlier than scheduled if the child develops new or worsening symptoms. (See ['Moderate symptoms'](#) below and ['Severe symptoms'](#) below.)

Moderate symptoms — In children with acute unilateral cervical lymphadenitis and moderate symptoms (eg, fever, warm and/or tender adenitis without fluctuance), we recommend a course of oral antimicrobial therapy after obtaining microbiologic specimens as indicated to guide therapy.

The evaluation of children with acute unilateral cervical lymphadenitis and moderate symptoms may include [\[4\]](#):

- Blood cultures if the child is febrile and ill-appearing.
- Cultures of draining skin lesions (if present); however, isolation of GAS from the skin does not necessarily confirm GAS as the cause of lymph node inflammation because the skin may be colonized with GAS [\[5\]](#).
- Throat culture (if they have exudative tonsillopharyngitis); however, isolation of GAS from the throat does not necessarily confirm GAS as the cause of lymph node inflammation because the throat may be colonized with GAS [\[5\]](#).

- Needle aspiration of the inflamed node (in children without exudative pharyngitis) or if the node is suppurative; samples should be sent for Gram stain, bacterial culture (aerobic and anaerobic), and susceptibilities; although mycobacteria more typically present as subacute/chronic infections, acid-fast bacilli stain and mycobacterial culture should be obtained if the specimen is adequate (the acute infection that brought the child to medical attention may be superimposed on a subacute/chronic process).

An infectious etiology is identified in 60 to 80 percent of patients who undergo needle aspiration for bacterial and mycobacterial culture [5-7]. Negative cultures do not absolutely exclude anaerobic infection, particularly in older children with poor oral hygiene or periodontal disease because anaerobes are fastidious organisms that require proper bacteriologic techniques for isolation [8].

We suggest that oral empiric antimicrobial therapy for children with acute unilateral cervical lymphadenitis and moderate symptoms include coverage for *S. aureus* and GAS. Coverage for anaerobes should be included in children with periodontal disease or poor oral hygiene. The choice of empiric regimen is influenced by the likelihood of methicillin- or clindamycin-resistant *S. aureus* (table 6). Antimicrobial treatment should be adjusted according to the culture and susceptibility results once they are available. The total length of therapy is usually 10 to 14 days. (See "[Methicillin-resistant Staphylococcus aureus infections in children: Epidemiology and clinical spectrum](#)", section on 'CA-MRSA strains' and "[Suspected Staphylococcus aureus and streptococcal skin and soft tissue infections in children >28 days: Evaluation and management](#)", section on 'Management approach'.)

Referral to a dentist may be warranted for children with underlying periodontal disease and/or poor oral hygiene [1].

Follow-up within 48 to 72 hours is necessary to ensure clinical response (eg, decreased maximum daily temperature and decreased inflammation and tenderness of the node) [2]. However, it may take four to six weeks for the lymph node to regress in size.

Failure to improve within 48 to 72 hours may indicate infection with a resistant organism (eg, methicillin-resistant or clindamycin-resistant *S. aureus*). If not performed previously, needle aspiration for Gram stain, culture, and susceptibilities may be indicated [9]. It may be necessary to broaden antimicrobial therapy to include coverage for resistant organisms, or less common organisms if clinically indicated [10]. (See '[Additional evaluation for persistence or uncertain etiology](#)' below.)

Occasionally, symptoms progress despite appropriate antimicrobial therapy and the patient requires hospitalization, parenteral therapy, and an incision and drainage procedure. Antimicrobial therapy is usually continued for seven days after the time of drainage.

Severe symptoms — For most children who have acute unilateral cervical lymphadenitis and severe symptoms (eg, ill-appearing, fever, fluctuant nodes, or concomitant cellulitis), we recommend antimicrobial therapy after drainage of the inflamed node. It is also important to consider Kawasaki disease in the differential diagnosis, given the importance of early treatment to prevent complications. Enlarged lymph nodes associated with Kawasaki disease may not be particularly inflamed or fluctuant. Clinicians with the most experience taking care of patients with Kawasaki disease should be consulted as early in the course of the evaluation of

suspected Kawasaki disease as possible. These clinicians may include pediatric rheumatologists, infectious disease specialists, cardiologists, and/or hospitalists, depending upon the institution. (See "[Kawasaki disease: Clinical features and diagnosis](#)" and "[Kawasaki disease: Initial treatment and prognosis](#)".)

The evaluation of children with acute unilateral cervical lymphadenitis and severe symptoms generally includes:

- Blood cultures.
- Drainage of fluctuant lymph node – Incision and drainage is preferred to needle aspiration to reduce the likelihood of reaccumulation of pus; children who undergo incision and drainage often require hospitalization and parenteral antimicrobial therapy for several days.

Abscess fluid and lymph node tissue (if obtained) should be sent for Gram stain, bacterial culture (aerobic and anaerobic), and susceptibilities; mycobacterial and fungal stains and cultures (mycobacteria and fungi more typically cause subacute/chronic lymphadenitis, but the acute infection that brought the child to medical attention may be superimposed on a subacute/chronic process); and histopathologic examination.

Ultrasonography of the lymph node may be useful in detecting the presence and extent of abscess if fluctuance is not obvious by manual examination. Some surgeons may request computed tomography with contrast before performing incision and drainage to detect unappreciated deep loculations.

- ESR and/or CRP may be helpful in monitoring the course of infection and making decisions about switching from parenteral to oral antimicrobial therapy.
- If Kawasaki disease is a consideration, echocardiogram and electrocardiogram should be obtained [11]. (See "[Kawasaki disease: Clinical features and diagnosis](#)".)

We suggest that empiric antimicrobial therapy for children with acute unilateral cervical lymphadenitis and severe symptoms be administered parenterally and include coverage for *S. aureus* and GAS. Coverage for anaerobes should be included in children with periodontal disease or poor oral hygiene. The choice of empiric regimen is influenced by the results of the Gram stain and the likelihood of methicillin- or clindamycin-resistant *S. aureus* (table 6). Antimicrobial treatment should be adjusted according to the culture and susceptibility results once they are available.

Children who are receiving appropriate antimicrobial therapy should have a clinical response within 48 to 72 hours (eg, decreased fever, decreased ESR/CRP [if previously measured]) [1].

After a few days of intravenous therapy, a switch usually can be made to oral therapy, guided by the results of culture, to complete a total of 10 to 14 days of therapy. Transition to oral therapy depends upon:

- The clinical course (resolution of fever, decreased pain, decreased swelling and redness)
- Improvement in ESR and CRP if previously measured
- Availability of an equivalent oral therapy

If the child fails to respond to empiric therapy, uncommon and rare infectious causes ([table 5](#)) and noninfectious causes ([table 2](#)) of acute unilateral cervical lymphadenitis must be considered. If cultures remain negative, empiric antimicrobial therapy may need to be broadened to include coverage for resistant organisms (eg, methicillin-resistant *S. aureus*). The history should be reviewed, with special attention to the following conditions:

- Tularemia (see ["Tularemia: Microbiology, epidemiology, and pathogenesis"](#) and ["Tularemia: Clinical manifestations, diagnosis, treatment, and prevention"](#))

If tularemia is a consideration and initial serologic testing is negative, repeat serologic testing may be warranted because seroconversion occurs 10 to 20 days after infection [[12,13](#)].

- Alpha *Streptococcus*, associated with oral lesions
- *Pasteurella multocida* (see ["Pasteurella infections"](#))
- *Y. pestis* (see ["Epidemiology, microbiology and pathogenesis of plague \(Yersinia pestis infection\)"](#) and ["Clinical manifestations, diagnosis, and treatment of plague \(Yersinia pestis infection\)"](#))
- *Yersinia enterocolitica* (see ["Epidemiology of yersiniosis"](#) and ["Clinical manifestations and diagnosis of Yersinia infections"](#))
- Gram-negative bacilli, associated with history of ear, nose, and throat infections; the isolation of gram-negative bacilli (eg, *Serratia* species) should prompt consideration of underlying immunodeficiency
- Anthrax (see ["Microbiology, pathogenesis, and epidemiology of anthrax"](#) and ["Clinical manifestations and diagnosis of anthrax"](#))

Surgical excision, drainage, or biopsy may be necessary to obtain microbiologic specimens to guide changes to antimicrobial therapy. (See ["Additional evaluation for persistence or uncertain etiology"](#) below.)

Subacute/chronic — Unilateral subacute/chronic cervical lymphadenitis is usually caused by cat scratch disease or nontuberculous mycobacterial (NTM) infection ([table 7](#)) [[1,14](#)]. However, the possibility of leukemia or lymphoma and other malignancies must be considered, particularly in adolescents ([table 2](#)). Bilateral subacute/chronic cervical lymphadenitis is usually caused by EBV or CMV ([table 8](#)).

Information from the history, physical examination, and initial evaluation (eg, TST, serology) help to distinguish among these possibilities ([table 2](#) and [table 7](#) and [table 8](#)). (See ["Cervical lymphadenitis in children: Etiology and clinical manifestations"](#), section on 'Subacute/chronic unilateral' and ["Cervical lymphadenitis in children: Etiology and clinical manifestations"](#), section on 'Neoplasm'.)

Evaluation — Our initial evaluation of children with subacute/chronic cervical lymphadenitis generally includes:

- CBC with differential and smear, ESR, and/or CRP (all of which may provide information about inflammation, bone marrow suppression or infiltration, and systemic involvement)

- Hepatic panel
- Uric acid and lactate dehydrogenase (as a preliminary evaluation to exclude malignancy)
- TST with intermediate (5 tuberculin unit) purified protein derivative [15]

Children who respond with 5 to 15 mm of induration at 48 hours may have NTM infection or tuberculosis (depending upon their risk for tuberculosis), whereas those with ≥ 15 mm induration usually have tuberculosis; however, reactions of 10 to 20 mm may occur with NTM [15-18]. (See ["Nontuberculous mycobacterial lymphadenitis in children", section on 'M. tuberculosis'](#) and ["Tuberculous lymphadenitis", section on 'Cervical lymphadenopathy'.](#))

IGRA tests may be useful in differentiating tuberculosis from NTM in children with positive TST; IGRA tests usually are positive with tuberculosis but negative with NTM, with rare exception (eg, *Mycobacterium kansasii*, *Mycobacterium marinum*, *Mycobacterium szulgai*, *Mycobacterium flavescens*) [19]. (See ["Latent tuberculosis infection in children", section on 'Interferon-gamma release assays'](#) and ["Tuberculosis disease in children", section on 'Interferon-gamma release assays'.](#))

Initial testing for children with subacute/chronic cervical lymphadenitis also may include:

- Serologic testing for HIV, EBV, and CMV (if the lymphadenitis is bilateral)
- Serologic testing for *Bartonella henselae* if there is a clinical suspicion of cat scratch disease (see ["Microbiology, epidemiology, clinical manifestations, and diagnosis of cat scratch disease", section on 'Approach to diagnosis'](#))
- Serology for tularemia, toxoplasmosis, or plague (*Y. pestis*) if indicated based on history or examination; although tularemia and *Y. pestis* typically cause acute cervical lymphadenitis, they should be considered in children with subacute/chronic lymphadenitis because they may require treatment (see ["Tularemia: Clinical manifestations, diagnosis, treatment, and prevention"](#) and ["Toxoplasmosis: Acute systemic disease"](#) and ["Clinical manifestations, diagnosis, and treatment of plague \(Yersinia pestis infection\)"](#))

If no etiology is identified with the above tests, excisional biopsy for histopathology, bacterial, mycobacterial, and fungal stains and cultures is usually indicated. (See ["Additional evaluation for persistence or uncertain etiology"](#) below.)

Management — The initial management of children with subacute/chronic cervical lymphadenitis depends upon the suspected etiology.

Suspected malignancy — Excisional biopsy should occur as early in the course as possible if malignancy is suspected. (See ["Additional evaluation for persistence or uncertain etiology"](#) below.)

Malignancy should be suspected in children with unilateral, nontender, hard, persistent or progressive cervical lymphadenopathy and/or associated constitutional symptoms (eg, weight loss, fever, fatigue). Lack of evidence of viral infection (eg, HIV, EBV, CMV) increases suspicion for malignancy. (See ["Cervical lymphadenitis in](#)

[children: Etiology and clinical manifestations", section on 'Neoplasm' and "Clinical assessment of the child with suspected cancer", section on 'Lymphadenopathy'.](#))

Suspected NTM — The clinical appearance of NTM adenitis, especially when the overlying skin becomes violaceous and thin, is so characteristic that the diagnosis can frequently be made based upon the history and physical examination ([picture 9](#)) [20]. Excisional biopsy of the involved lymph node can provide a definitive diagnosis of NTM adenitis and is the preferred treatment, when it can be performed safely. Incision and complete curettage is an alternative when excisional biopsy cannot be performed. Incision and drainage are contraindicated, due to the risk of developing a chronically draining fistula.

The clinical features, diagnosis, and management of NTM lymphadenitis in children are discussed separately. (See ["Nontuberculous mycobacterial lymphadenitis in children"](#).)

Suspected cat scratch disease — When cat scratch disease is suspected but not confirmed, empiric therapy should provide coverage for *S. aureus* and GAS ([table 6](#)), as well as for cat scratch disease.

Oral agents that may be used for cat scratch disease include [azithromycin](#), [rifampin](#), and [trimethoprim-sulfamethoxazole](#). Rifampin has an advantage of providing additive therapy to other antimicrobials against *S. aureus* and GAS. The treatment of cat scratch disease is discussed separately. (See ["Treatment of cat scratch disease", section on 'Lymphadenitis'](#).)

Surgical excision is not usually necessary for cat scratch lymphadenitis. However, painful, suppurative nodes can be treated with needle aspiration(s) for symptomatic relief.

ADDITIONAL EVALUATION FOR PERSISTENCE OR UNCERTAIN ETIOLOGY

If after the initial evaluation the etiology of the adenitis remains uncertain, or the adenitis has persisted for six to eight weeks with no response to antimicrobial therapy, additional testing may be indicated to assess uncommon or rare infectious causes ([table 1](#)) and noninfectious causes ([table 2](#)) of cervical lymphadenitis [2].

Depending upon which studies were performed as part of the initial evaluation and risk factors identified in the initial evaluation or re-evaluation, additional testing may include:

- Repeat complete blood count (CBC) with differential (which may provide information about inflammation, bone marrow suppression or infiltration, and systemic involvement)
- Rapid plasma reagin or venereal disease research laboratory test for syphilis
- Serology for Epstein-Barr virus, cytomegalovirus, human herpesvirus-6, HIV, histoplasmosis, coccidiomycosis, toxoplasmosis, tularemia, *B. henselae*, and brucella
- Chest radiograph (looking for mediastinal lymph nodes or mass)
- Excisional biopsy – Indications for excisional biopsy may include:

- Suspicion of malignancy (eg, CBC with blasts or abnormal counts; mediastinal mass or mediastinal lymphadenopathy on chest radiograph, constitutional symptoms, supraclavicular or lower cervical lymphadenitis, matted lymphadenopathy)
- Suspicion of tuberculous or nontuberculous mycobacterial lymphadenitis
- Persistent (more than six to eight weeks without decreasing in size) or enlarging adenopathy with uncertain diagnosis

Excisional biopsy of the largest and firmest palpable node should occur as early in the course as possible if malignancy or mycobacterial infection is suspected [21]. (See ["Nontuberculous mycobacterial lymphadenitis in children", section on 'Diagnosis'.](#))

The biopsy should be performed at a medical center specializing in the care of children, and the pathologist should know in advance there will be a lymph node biopsy. This will ensure the proper smears, stains, and cultures are performed. Biopsy specimens should be submitted for bacterial, mycobacterial, and fungal stains and cultures and histopathologic examination. Parts of the sample should not be fixed at the time of excision to allow for sensitive marker studies, such as immunophenotyping, cytogenetics, and molecular studies.

PROGNOSIS

Cervical lymphadenitis spontaneously regresses in most children over the course of several weeks [22-24]. Reactivation of inflammation may occur in children who have conditions that predispose to infection (eg, dermatitis, infestation, foreign body) or if there is an occult source of infection that was not adequately treated (eg, dental abscess).

Complications — Delayed diagnosis and initiation of appropriate therapy may result in a prolonged clinical course or complications [2]. Persistent and recurrent lymphadenitis is the most frequent complication [25]. Other complications vary depending upon the underlying etiology and include:

- Nontuberculous *Mycobacteria* – Development of a sinus tract and/or disseminated disease [26-28] (see ["Nontuberculous mycobacterial lymphadenitis in children", section on 'Clinical features'](#) and ["Disseminated nontuberculous mycobacterial \(NTM\) infections and NTM bacteremia in children"](#))
- *S. aureus* – Abscess formation, cellulitis, bacteremia [5,29]
- Group A *Streptococcus* – Abscess formation, cellulitis, bacteremia, acute glomerulonephritis [6]

INFORMATION FOR PATIENTS

UpToDate offers two types of patient education materials, "The Basics" and "Beyond the Basics." The Basics patient education pieces are written in plain language, at the 5th to 6th grade reading level, and they answer the

four or five key questions a patient might have about a given condition. These articles are best for patients who want a general overview and who prefer short, easy-to-read materials. Beyond the Basics patient education pieces are longer, more sophisticated, and more detailed. These articles are written at the 10th to 12th grade reading level and are best for patients who want in-depth information and are comfortable with some medical jargon.

Here are the patient education articles that are relevant to this topic. We encourage you to print or email these topics to your patients. (You can also locate patient education articles on a variety of subjects by searching on "patient info" and the keyword[s] of interest.)

- Basics topic (see ["Patient education: Swollen neck nodes in children \(The Basics\)"](#))

SUMMARY AND RECOMMENDATIONS

- There are numerous infectious ([table 1](#)) and noninfectious causes ([table 2](#)) of cervical lymphadenitis. (See ['Causes'](#) above.)
- Important aspects of the history and examination include onset, laterality, duration, and qualities of the lymphadenitis; associated symptoms (eg, fever, weight loss) and examination findings (eg, conjunctivitis, rash, hepatosplenomegaly); immunizations status; and exposures ([table 3](#)). (See ['History'](#) above and ['Physical examination'](#) above.)
- Acute bilateral cervical lymphadenitis is usually caused by a self-limited viral upper respiratory infection ([table 4](#)) and requires only monitoring unless it is accompanied by severe symptoms, progresses, or persists. Acute bilateral cervical lymphadenitis usually does not require specific treatment. (See ['Acute bilateral'](#) above.)
- Acute unilateral lymphadenitis is usually caused by *Staphylococcus aureus* or group A *Streptococcus* (GAS) ([table 5](#)). The evaluation and management depend upon the child's clinical status and the course of lymphadenitis. (See ['Acute unilateral'](#) above.)
 - Children who are well-appearing and have slightly enlarged nodes with minimal tenderness can be followed clinically with serial examination every few weeks until regression. (See ['Minimal symptoms'](#) above.)
 - For children who have moderate symptoms (warm and/or tender lymphadenitis without fluctuance), the evaluation is tailored to the clinical findings and may include blood cultures, cultures of draining skin lesions, throat culture, needle aspiration for Gram stain and cultures (aerobic and anaerobic), and mycobacterial culture and stain for acid-fast bacilli (if the specimen is adequate). (See ['Moderate symptoms'](#) above.)
 - For children who have severe symptoms (ill-appearing, fever, fluctuant nodes, concomitant cellulitis), the evaluation usually includes blood cultures, drainage of the inflamed node (Gram stain, bacterial, cultures [aerobic and anaerobic] and susceptibilities, mycobacterial and fungal stains and cultures,

and histopathologic examination), erythrocyte sedimentation rate (ESR), and/or C-reactive protein (CRP). Echocardiogram and electrocardiogram should be obtained if Kawasaki disease is a consideration. (See ['Severe symptoms'](#) above.)

- We recommend that children with moderate or severe symptoms be treated with antimicrobial therapy (**Grade 1B**). Initial empiric therapy should provide coverage for *S. aureus* and GAS; coverage for anaerobes should be included in patients with periodontal disease or poor oral hygiene ([table 6](#)). (See ['Moderate symptoms'](#) above and ['Severe symptoms'](#) above.)
- Children with acute unilateral lymphadenitis who are receiving appropriate antimicrobial therapy usually manifest decreased inflammation and tenderness of the node and decreased maximum daily temperature within 48 to 72 hours. Failure to improve within 48 to 72 hours may indicate infection with a resistant organism, particularly methicillin- or clindamycin-resistant *S. aureus*; an uncommon or rare infectious cause ([table 5](#)); or a noninfectious cause ([table 2](#)). (See ['Moderate symptoms'](#) above and ['Severe symptoms'](#) above.)
- Unilateral subacute/chronic cervical lymphadenitis is usually caused by cat scratch disease or nontuberculous mycobacterial (NTM) infection. However, the possibility of malignancy must be considered, particularly in adolescents. Bilateral subacute/chronic cervical lymphadenitis is usually caused by Epstein-Barr virus (EBV) or cytomegalovirus (CMV). (See ['Subacute/chronic'](#) above.)
 - The initial evaluation of children with subacute/chronic cervical lymphadenitis usually includes a complete blood count with differential and smear; ESR and/or CRP; hepatic panel; uric acid and lactate dehydrogenase; [tuberculin skin test](#); serologic testing for HIV, EBV, and CMV (if bilateral); and serologic testing for *Bartonella henselae*, tularemia, toxoplasmosis, or plague (if indicated by clinical findings).
 - The initial management of children with subacute/chronic cervical lymphadenitis depends upon the suspected etiology:
 - Excisional biopsy should occur as early in the course as possible if malignancy is suspected. (See ['Suspected malignancy'](#) above.)
 - Excisional biopsy is also the preferred treatment for NTM lymphadenitis when it can be performed safely. (See ["Nontuberculous mycobacterial lymphadenitis in children", section on 'Management'](#).)
 - When cat scratch disease is suspected but not confirmed, empiric therapy should provide coverage for *S. aureus* and GAS ([table 6](#)) as well as for cat scratch disease (eg, [azithromycin](#), [rifampin](#), or [trimethoprim-sulfamethoxazole](#)). (See ['Suspected cat scratch disease'](#) above and ["Treatment of cat scratch disease", section on 'Lymphadenitis'](#).)
- For children in whom the etiology of lymphadenitis remains uncertain after the initial evaluation or the lymphadenitis has persisted for six to eight weeks with no response to antimicrobial therapy, additional testing, including excisional biopsy, may be indicated to assess uncommon or rare infectious ([table 1](#)) and

noninfectious causes ([table 2](#)) of cervical lymphadenitis. (See '[Additional evaluation for persistence or uncertain etiology](#)' above.)

ACKNOWLEDGMENT

The editorial staff at UpToDate, Inc. would like to acknowledge Dr. Douglas Swanson, who contributed to an earlier version of this topic review.

Use of UpToDate is subject to the [Subscription and License Agreement](#).

REFERENCES

1. [Leung AK, Davies HD. Cervical lymphadenitis: etiology, diagnosis, and management. Curr Infect Dis Rep 2009; 11:183.](#)
2. Healy CM, Baker CJ. Cervical lymphadenitis. In: Feigin and Cherry's Textbook of Pediatric Infectious Diseases, 8th ed, Cherry JD, Harrison G, Kaplan SL, et al (Eds), Elsevier, Philadelphia 2018. p.124.
3. [Neff L, Newland JG, Sykes KJ, et al. Microbiology and antimicrobial treatment of pediatric cervical lymphadenitis requiring surgical intervention. Int J Pediatr Otorhinolaryngol 2013; 77:817.](#)
4. [Dulin ME, Kennard TP, Leach L, Williams R. Management of cervical lymphadenitis in children. Am Fam Physician 2008; 78:1097.](#)
5. [Barton LL, Feigin RD. Childhood cervical lymphadenitis: a reappraisal. J Pediatr 1974; 84:846.](#)
6. [DAJANI AS, GARCIA RE, WOLINSKY E. Etiology of cervical lymphadenitis in children. N Engl J Med 1963; 268:1329.](#)
7. [Scobie WG. Acute suppurative adenitis in children: a review of 964 cases. Scott Med J 1969; 14:352.](#)
8. [Brook I. Aerobic and anaerobic bacteriology of cervical adenitis in children. Clin Pediatr \(Phila\) 1980; 19:693.](#)
9. [Gosche JR, Vick L. Acute, subacute, and chronic cervical lymphadenitis in children. Semin Pediatr Surg 2006; 15:99.](#)
10. [Miller LG, Daum RS, Creech CB, et al. Clindamycin versus trimethoprim-sulfamethoxazole for uncomplicated skin infections. N Engl J Med 2015; 372:1093.](#)
11. [Campbell RM, Douglas PS, Eidem BW, et al. ACC/AAP/AHA/ASE/HRS/SCAI/SCCT/SCMR/SOPE 2014 appropriate use criteria for initial transthoracic echocardiography in outpatient pediatric cardiology: a report of the American College of Cardiology Appropriate Use Criteria Task Force, American Academy of](#)

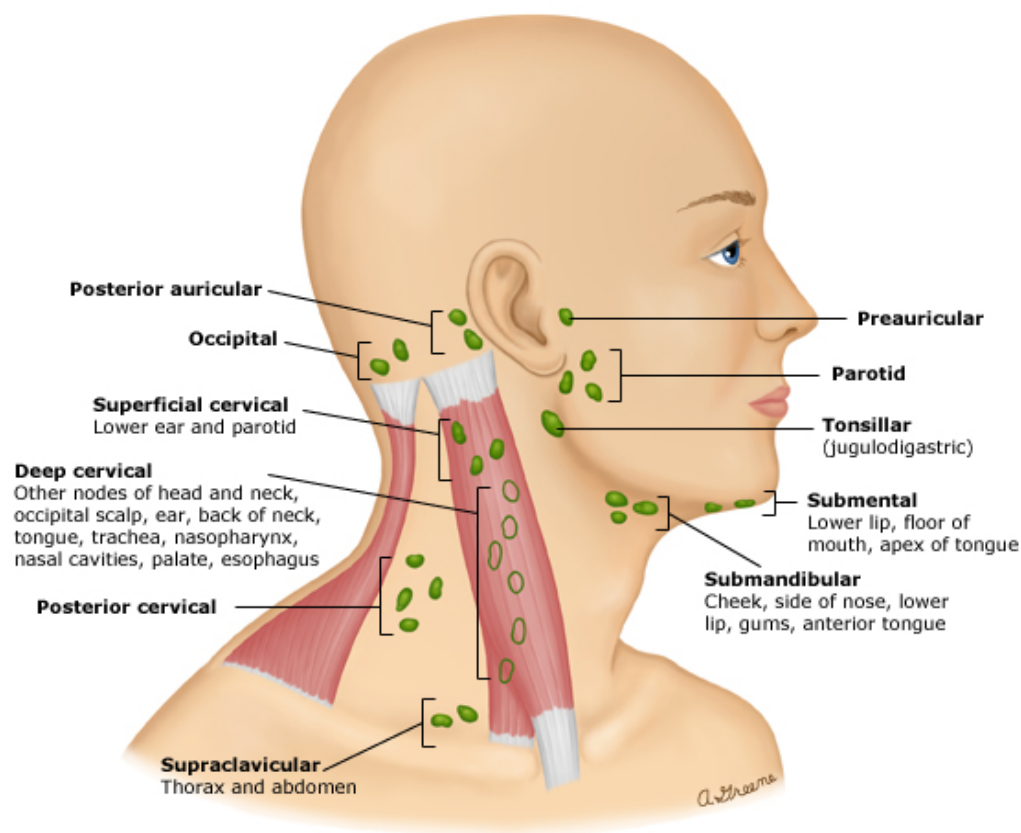
- [Pediatrics](#), [American Heart Association](#), [American Society of Echocardiography](#), [Heart Rhythm Society](#), [Society for Cardiovascular Angiography and Interventions](#), [Society of Cardiovascular Computed Tomography](#), [Society for Cardiovascular Magnetic Resonance](#), and [Society of Pediatric Echocardiography](#). *J Am Coll Cardiol* 2014; 64:2039.
12. [Snowden J, Stovall S. Tularemia: retrospective review of 10 years' experience in Arkansas. Clin Pediatr \(Phila\) 2011; 50:64.](#)
 13. World Health Organization. WHO guidelines on tularemia. Geneva, Switzerland: World Health Organization; 2007. <http://www.cdc.gov/tularemia/resources/whotularemiamanual.pdf>. (Accessed on September 05, 2014).
 14. [Choi P, Qin X, Chen EY, et al. Polymerase chain reaction for pathogen identification in persistent pediatric cervical lymphadenitis. Arch Otolaryngol Head Neck Surg 2009; 135:243.](#)
 15. [Griffith DE, Aksamit T, Brown-Elliott BA, et al. An official ATS/IDSA statement: diagnosis, treatment, and prevention of nontuberculous mycobacterial diseases. Am J Respir Crit Care Med 2007; 175:367.](#)
 16. [Margileth AM. The use of purified protein derivative mycobacterial skin test antigens in children and adolescents: purified protein derivative skin test results correlated with mycobacterial isolates. Pediatr Infect Dis 1983; 2:225.](#)
 17. [Perlman DC, D'Amico R, Salomon N. Mycobacterial Infections of the Head and Neck. Curr Infect Dis Rep 2001; 3:233.](#)
 18. [Lindeboom JA, Kuijper EJ, Prins JM, et al. Tuberculin skin testing is useful in the screening for nontuberculous mycobacterial cervicofacial lymphadenitis in children. Clin Infect Dis 2006; 43:1547.](#)
 19. [Starke JR, Committee On Infectious Diseases. Interferon- \$\gamma\$ release assays for diagnosis of tuberculosis infection and disease in children. Pediatrics 2014; 134:e1763.](#)
 20. [Fraser L, Moore P, Kubba H. Atypical mycobacterial infection of the head and neck in children: a 5-year retrospective review. Otolaryngol Head Neck Surg 2008; 138:311.](#)
 21. [Leung AK, Robson WL. Childhood cervical lymphadenopathy. J Pediatr Health Care 2004; 18:3.](#)
 22. [Schaad UB, Votteler TP, McCracken GH Jr, Nelson JD. Management of atypical mycobacterial lymphadenitis in childhood: a review based on 380 cases. J Pediatr 1979; 95:356.](#)
 23. [Flint D, Mahadevan M, Barber C, et al. Cervical lymphadenitis due to non-tuberculous mycobacteria: surgical treatment and review. Int J Pediatr Otorhinolaryngol 2000; 53:187.](#)
 24. [Maltezou HC, Spyridis P, Kafetzis DA. Nontuberculous mycobacterial lymphadenitis in children. Pediatr Infect Dis J 1999; 18:968.](#)

25. [Wolinsky E. Mycobacterial lymphadenitis in children: a prospective study of 105 nontuberculous cases with long-term follow-up. Clin Infect Dis 1995; 20:954.](#)
26. [BLACK BG, CHAPMAN JS. CERVICAL ADENITIS IN CHILDREN DUE TO HUMAN AND UNCLASSIFIED MYCOBACTERIA. Pediatrics 1964; 33:887.](#)
27. [Ord RJ, Matz GJ. Tuberculous cervical lymphadenitis. Arch Otolaryngol 1974; 99:327.](#)
28. [Kent DC. Tuberculous lymphadenitis: not a localized disease process. Am J Med Sci 1967; 254:866.](#)
29. [Brook AH, Winter GB. Cervico-facial suppurative lymphadenitis due to staphylococcal infection in childhood. Br J Oral Surg 1971; 8:257.](#)

Topic 6061 Version 33.0

GRAPHICS

Lymph nodes of the head and neck



This drawing schematically depicts the major lymph nodes in the head and neck area that are likely to be enlarged on physical examination in patients with various local or systemic diseases. The major nodal groups are shown here in bold, with the areas draining into these nodal groups noted when appropriate. While enlargement of both the left and right supraclavicular lymph nodes may reflect disease in the thorax, left supraclavicular nodal enlargement, because of its drainage pattern, may also reflect the presence of abdominal involvement (ie, Virchow node).

Graphic 69528 Version 4.0

Infectious causes of cervical lymphadenitis in children

Presentation	Common	Uncommon	Rare
Acute bilateral	Rhinovirus Epstein-Barr virus*¶ Cytomegalovirus*¶ Herpes simplex virus Adenovirus Enterovirus <i>Mycoplasma pneumoniae</i> Group A <i>Streptococcus</i> <i>Arcanobacterium haemolyticum</i> Influenza	Roseola¶ Parvovirus B19¶	<i>Corynebacterium diphtheriae</i> Rubella¶ Measles Mumps¶
Acute unilateral	<i>Staphylococcus aureus</i> Group A <i>Streptococcus</i> Anaerobic bacteria	Group B <i>Streptococcus</i> Tularemia* Alpha <i>Streptococcus</i> <i>Pasteurella multocida</i> <i>Yersinia pestis</i> ¶ Gram-negative bacilli	<i>Yersinia enterocolitica</i> * Anthrax
Chronic unilateral	Nontuberculous mycobacteria Cat scratch disease	Toxoplasmosis¶ Tuberculosis¶ Actinomycosis	<i>Nocardia brasiliensis</i> Aspergillosis Sporotrichosis
Chronic bilateral	Epstein-Barr virus¶ Cytomegalovirus¶	HIV¶ Toxoplasmosis¶ Tuberculosis¶ Syphilis¶	Brucellosis¶ Histoplasmosis¶

HIV: human immunodeficiency virus.

* Infection can persist and become more chronic in appearance.

¶ Often associated with generalized lymphadenopathy.

Graphic 56712 Version 8.0

Noninfectious causes of cervical lymphadenopathy in children

Condition	Possible associated clinical features
Malignancy	
Lymphoma or leukemia	Persistent, or progressive, nontender cervical or generalized lymphadenopathy; constitutional symptoms (eg, fever, weight loss, fatigue)
Neuroblastoma	Constitutional symptoms (fever, weight loss); abdominal mass; GI symptoms; proptosis; periorbital ecchymoses; Horner syndrome; opsoclonus myoclonus ataxia; palpable subcutaneous nodules; bone pain; hypertension; unilateral nasal obstruction
Rhabdomyosarcoma	Localized, painless, enlarging mass; proptosis; ophthalmoplegia; nasal, aural, or sinus obstruction (without drainage)
Thyroid cancer	History of external radiation to the head and neck; hoarseness; dysphagia; medullary thyroid cancer may be associated with multiple endocrine neoplasias
Collagen vascular disease	
Juvenile idiopathic arthritis	Arthritis/arthralgia; fever; rash; other systemic involvement (eg, hepatosplenomegaly, pericarditis, etc)
Systemic lupus erythematosus	Arthritis/arthralgia; hematologic abnormalities (anemia, leukopenia, lymphopenia, thrombocytopenia); malar rash; oral ulcers; fever; renal disease
Drugs	
Phenytoin	Seizure disorder
Carbamazepine	Seizure disorder
Miscellaneous	
Kawasaki disease	Fever; rash; nonexudative conjunctivitis; enanthem; swelling of hands and feet
PFAPA	Recurrent fevers; aphthous stomatitis; pharyngitis; and adenitis
Kikuchi disease	Fever; rash; systemic symptoms (fatigue, weight loss); leukopenia; anemia; usually occurs in young women
Langerhans cell histiocytosis	Lytic bone lesions; rash (papular or eczematous); oral lesions (mass, gingivitis, ulcers, loose teeth); diabetes insipidus
Hemophagocytic lymphohistiocytosis	Hepatomegaly; rash; neurologic findings (seizures, mental status changes); anemia; thrombocytopenia; most frequent at age <10 months, but may occur in older children
Castleman disease	Lymph nodes may be >4 cm (1.6 inches); may have systemic symptoms (fever, night sweats, malaise); hepatosplenomegaly; anemia, thrombocytosis
Kimura disease	Painless subcutaneous masses in head and neck; eosinophilia; increased IgE
Postvaccination	Recent history of immunization (particularly diphtheria-tetanus-pertussis, polio, or typhoid fever vaccine)
Sarcoidosis	Extensive enlargement of cervical nodes; facial eruption (flat-topped papules); weight loss; lethargy; fatigue, cough; bone lesions (eg, cystic or sclerotic focal lesions, osteopenia, osteoporosis)

GI: gastrointestinal; PFAPA: periodic fever with aphthous stomatitis, pharyngitis, and adenitis syndrome; IgE: immunoglobulin E.

Graphic 77911 Version 11.0

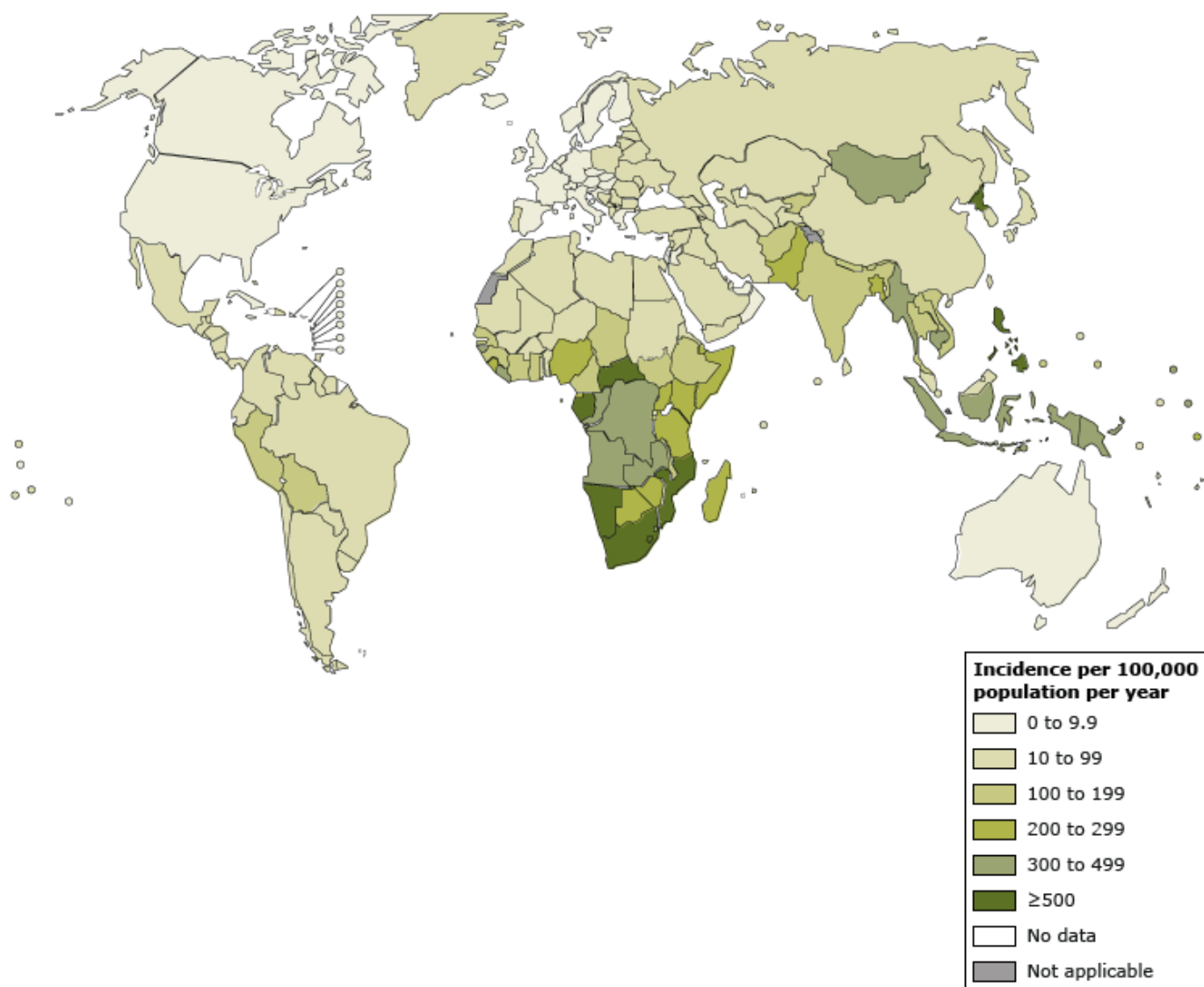
Important aspects of the history and examination in a child with cervical lymphadenopathy

Clinical feature	Potential significance
History	
Onset, laterality, and duration	Helps to narrow etiology
Constitutional symptoms (eg, weight loss, fatigue, malaise)	Malignancy, Kikuchi-Fujimoto disease, Castleman disease, sarcoidosis
Recurrent/chronic cough, hemoptysis	Tuberculosis
Arthritis/arthritis	Juvenile idiopathic arthritis, systemic lupus erythematosus
Nasal, aural, or sinus obstruction without drainage	Rhabdomyosarcoma
Immunizations status	Measles, mumps, rubella, diphtheria (if unimmunized); postvaccination lymphadenitis (if recently immunized, particularly with diphtheria-tetanus-pertussis, polio, or typhoid fever vaccine)
Exposures	
■ Ill contacts	Supports infectious etiology
■ Unpasteurized milk	Brucellosis, <i>Mycobacterium bovis</i>
■ Undercooked meats	Toxoplasmosis
■ Animals	Cats (cat scratch disease, <i>Pasteurella multocida</i> , toxoplasmosis); dogs (<i>P. multocida</i>) rabbits (tularemia); hamster (tularemia); goats (brucellosis); prairie dogs (plague)
■ Flea or tick bites	Plague, tularemia
■ Phenytoin, carbamazepine	Medication-related
■ Geographic location or travel	May need to consider less common causes (eg, tularemia, plague, tuberculosis)
Examination	
Lymph node qualities	
■ Soft, small, round, discrete, mobile, minimally tender	Suggestive of "reactive" lymphadenopathy
■ Isolated, asymmetric, tender, warm, erythematous	Suggestive of infection
■ Hard, nontender, fixed, matted to underlying structures	May indicate malignancy
Hepatosplenomegaly and involvement of noncervical nodes	Systemic infection (eg, EBV, CMV, HIV, histoplasmosis, tuberculosis, syphilis), juvenile idiopathic arthritis, Castleman disease
Conjunctivitis	Cat scratch disease, tularemia, adenovirus, Kawasaki disease, measles
Poor dental hygiene, periodontal disease, dental caries	Anaerobic infection
Loose teeth	Langerhans cell histiocytosis
Mouth sores/lesions	HSV, enterovirus, PFAPA, Kawasaki disease, Langerhans cell histiocytosis
Pharyngitis	GAS, EBV, PFAPA, diphtheria
Localized skin lesion	More common: <i>Staphylococcus aureus</i> , GAS, cat scratch disease, tularemia, HSV Less common: Nocardia, actinomycosis, sporotrichosis, plague, cutaneous diphtheria
Generalized rash	Systemic viral illness (eg, roseola, EBV, measles, rubella, parvovirus B19), Kawasaki disease, juvenile idiopathic arthritis, systemic lupus erythematosus, Langerhans cell histiocytosis, hemophagocytic lymphohistiocytosis

EBV: Epstein-Barr virus; CMV: cytomegalovirus; HIV: human immunodeficiency virus; HSV: herpes simplex virus, PFAPA: periodic fever with aphthous stomatitis, pharyngitis, and adenitis; GAS: group A *Streptococcus*.

Graphic 97722 Version 3.0

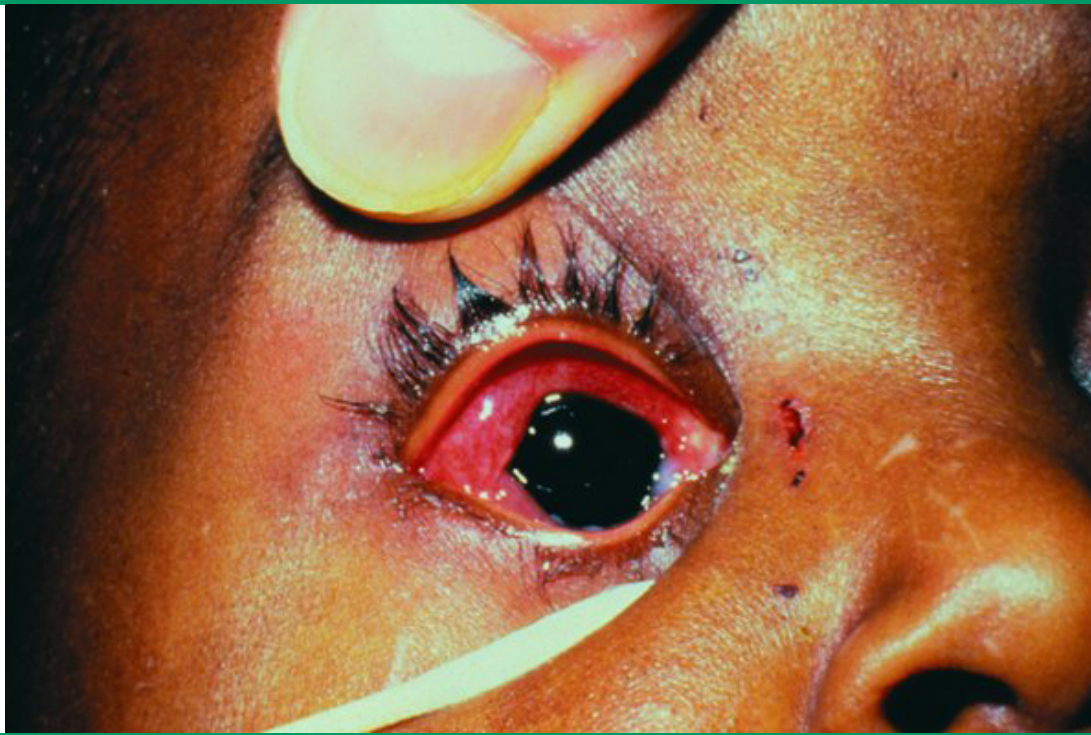Estimated tuberculosis incidence rates, by country, 2018



Reprinted from *Global Tuberculosis Report 2019*, World Health Organization, Copyright © 2019. Available at: https://www.who.int/tb/publications/global_report/en/ (Accessed on October 31, 2019).

Graphic 55097 Version 10.0

Parinaud oculoglandular syndrome

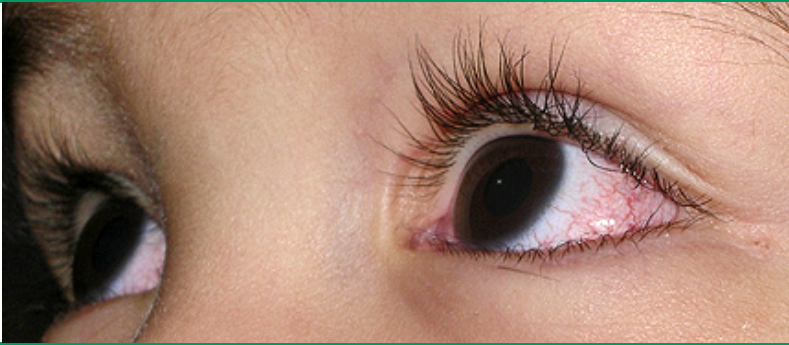

Parinaud oculoglandular syndrome. Severe diffuse conjunctival inflammation along with a superotemporal conjunctival granuloma is present in this child with cat-scratch disease. Note the skin abrasions near the nose, which were presumably caused by a cat scratch.

Reproduced with permission from: Conjunctival Infections and Inflammations. In: Wills Eye Institute: Cornea, Rapuano CJ (Ed), Lippincott Williams & Wilkins, Philadelphia 2011. Copyright © 2011 Lippincott Williams & Wilkins. www.lww.com.

Graphic 97723 Version 3.0

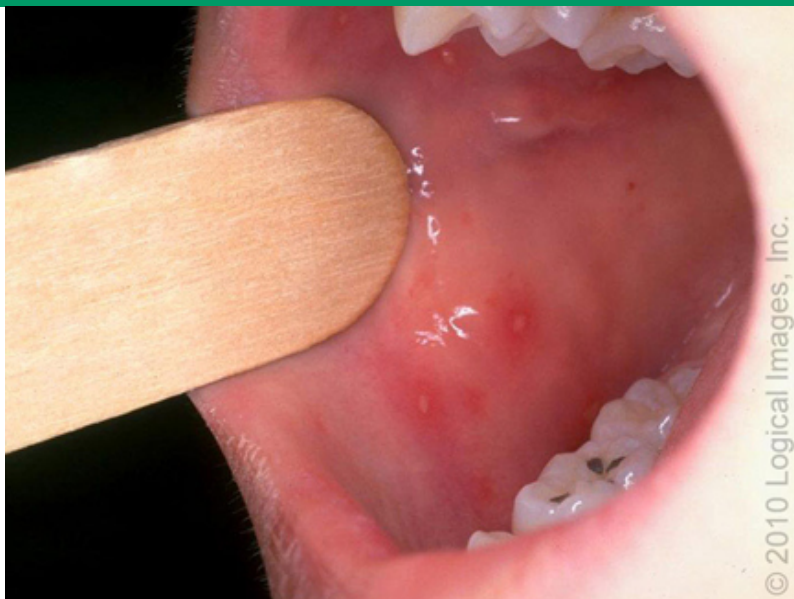Conjunctivitis in Kawasaki disease



Courtesy of Robert Sundel, MD.

Graphic 78898 Version 2.0

Hand-foot-and-mouth disease

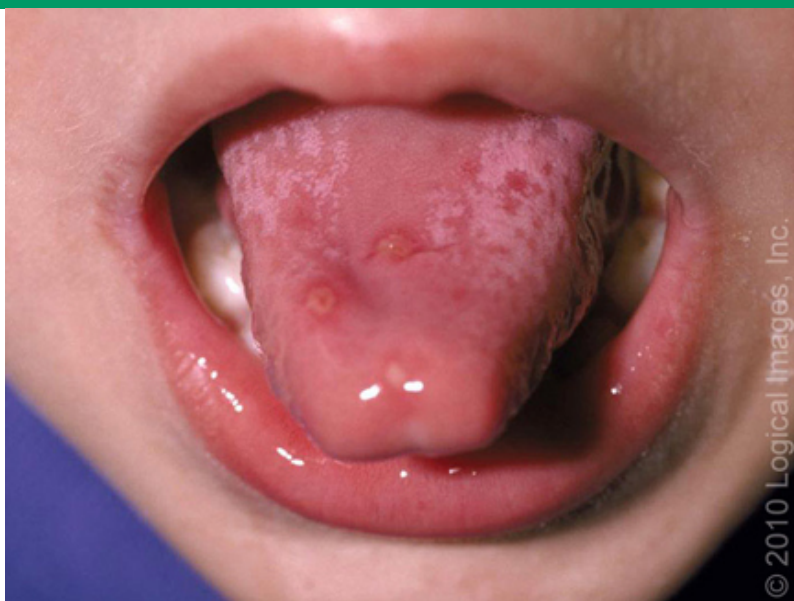

Small ulcers are present on the oral mucosa.

Reproduced with permission from: www.visualdx.com. Copyright VisualDx. All rights reserved.

Graphic 58566 Version 7.0

Hand-foot-and-mouth disease

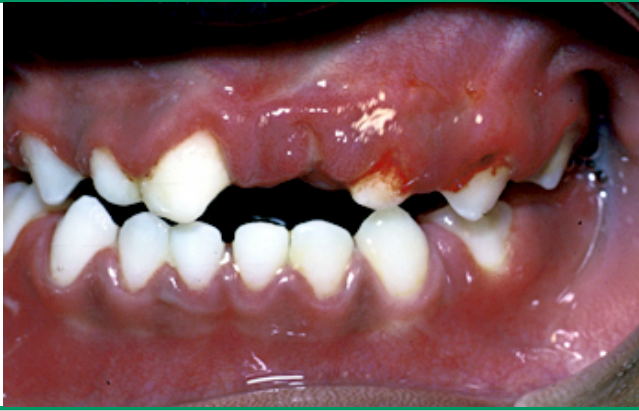

Multiple small ulcers are present on the tongue.

Reproduced with permission from: www.visualdx.com. Copyright VisualDx. All rights reserved.

Graphic 71314 Version 6.0

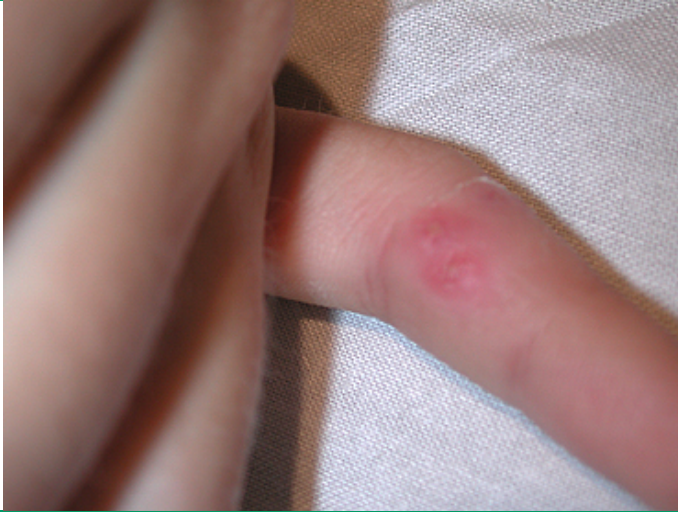Primary herpes simplex virus gingivostomatitis



Courtesy of Martha Ann Keels, DDS, PhD.

Graphic 58944 Version 1.0

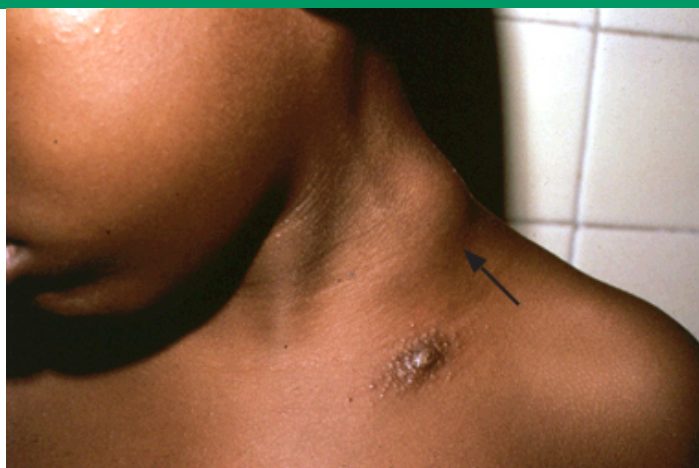Typical papular lesion on the finger of a child with cat scratch disease



Courtesy of Sheldon L Kaplan, MD.

Graphic 78770 Version 2.0

Cat scratch disease



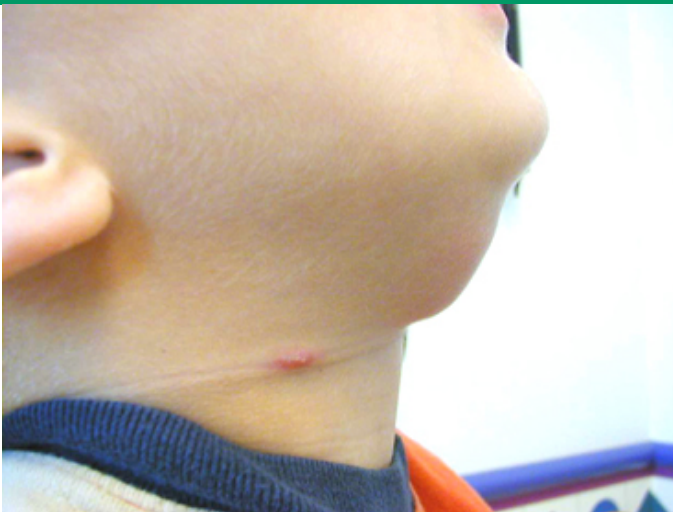This patient with cat scratch disease has a primary inoculation lesion and prominent cervical lymphadenopathy (arrow).

Courtesy of Joy D Jester. The Skin and Infection: A Color Atlas and Text, Sanders CV, Nesbitt LT Jr (Eds), Williams & Wilkins, Baltimore, 1995.

<http://www.lww.com>

Graphic 59249 Version 3.0

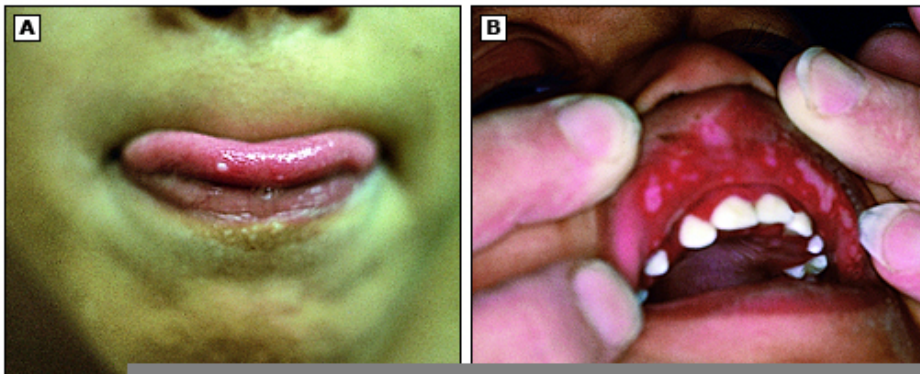
Tularemia adenitis



Ulceroglandular tularemia involving the submental node characterized by a papular lesion in the drainage field of the inflamed lymph node.

Graphic 52036 Version 1.0

Herpetic stomatitis



These three children demonstrate the spectrum of oral infection with herpes simplex virus, which ranges from asymptomatic to severe.

(A) The first patient has a single vesicle on his tongue.

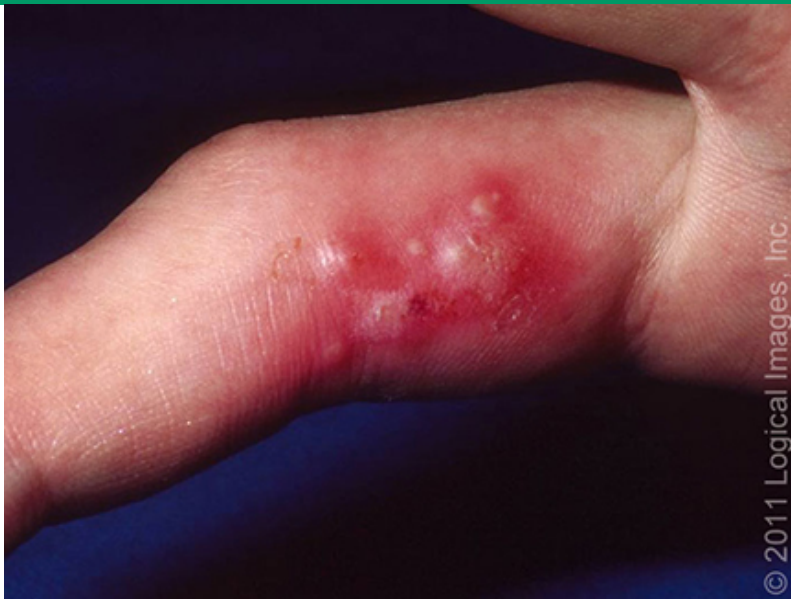(B) The second manifests widespread labial lesions.

(C) The third patient shows dissemination to the face. In the young girl with facial involvement, fluorescein dye is dripping from the left eye after its instillation in an attempt to identify the typical dendritic ulcer seen with herpetic keratitis.

Reproduced with permission from: Fleisher GR, Ludwig W, Baskin MN. Atlas of Pediatric Emergency Medicine. Philadelphia: Lippincott Williams & Wilkins, 2004. Copyright © 2004 Lippincott Williams & Wilkins.

Graphic 58542 Version 3.0

Herpetic whitlow

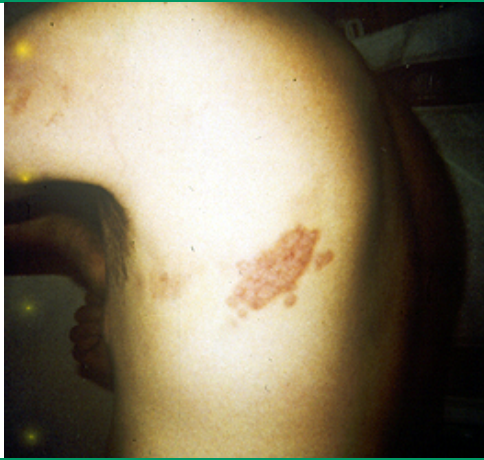

Grouped vesicles on an intensely erythematous base are characteristic of herpes simplex infection. The lesion is usually monolateral and is more often painful than pruritic.

Reproduced with permission from: www.visualdx.com. Copyright VisualDx. All rights reserved.

Graphic 52029 Version 8.0

Cutaneous sporotrichosis



Lesions on the back of a patient with cutaneous sporotrichosis who was thrown from his truck following a motor vehicle accident.

Courtesy of Carol A Kauffman, MD.

Graphic 74340 Version 3.0

Infectious causes of acute bilateral cervical lymphadenitis in children

Infection	Associated clinical features
Common causes	
Influenza virus	URI symptoms, fever
Epstein-Barr virus*¶	Infectious mononucleosis (malaise, headache, fever, tonsillopharyngitis, fatigue, splenomegaly)
Cytomegalovirus*¶	Mononucleosis-like illness
Herpes simplex virus	Gingivostomatitis or cold sore
Adenovirus	URI symptoms, pharyngitis, conjunctivitis
Enterovirus	URI symptoms, oral lesions, lesions on hands and feet
Rhinovirus	URI symptoms
Group A <i>Streptococcus</i>	Exudative pharyngitis
<i>Arcanobacterium haemolyticum</i>	Exudative pharyngitis, scarlatiniform rash; predominantly occurs in adolescents and young adults
<i>Mycoplasma pneumoniae</i>	Headache, malaise, fever, pharyngitis, cough
Uncommon causes	
Roseola¶	Fever, irritability, rash
Parvovirus B19¶	Fever, "slapped cheek" rash
Rare causes	
<i>Corynebacterium diphtheria</i>	Sore throat, malaise, fever, exudative pharyngitis, pseudomembrane; edema of the soft tissues of the neck
Rubella¶	Rash that spreads from face to trunk and extremities
Measles	Prodrome of fever, conjunctivitis, coryza, and cough followed by rash that spreads from face to trunk and extremities; lack of immunization, international travel
Mumps¶	Tenderness and swelling of parotid gland

URI: upper respiratory infection.

* Infection can persist and become more chronic in appearance.

¶ Often associated with generalized lymphadenopathy.

Graphic 97716 Version 1.0

Infectious causes of acute unilateral cervical lymphadenitis in children

Infectious agent	Clinical features
Common causes	
<i>Staphylococcus aureus</i>	Usually occurs in children <5 years; may have history of recent skin infection, upper respiratory infection, or facial trauma
Group A <i>Streptococcus</i>	Usually occurs in children <5 years; may have history of recent skin infection, upper respiratory infection, or facial trauma
Anaerobic bacteria (eg, actinomycosis; <i>Spirillum minor</i>)	Poor dental hygiene; periodontal disease
Uncommon causes	
Group B <i>Streptococcus</i>	Occurs in infants <3 months corrected gestational age; fever; irritability; poor feeding
Tularemia*	Contact with infected animal (eg, rabbit, pet hamsters) or bite of blood-sucking arthropod; may be papular lesion in the drainage field of the involved node
Alpha <i>Streptococcus</i>	Oral lesions
<i>Pasteurella multocida</i>	Cat or dog exposure (bite, lick, scratch)
<i>Yersinia pestis</i> [¶] (bubonic plague)	Intensely inflamed lymph node (red, swollen, tender) without fluctuance; possible, eschar, pustule, or necrotic lesion at site of flea bite
Gram-negative bacilli	History of ear, nose, and throat infections; may indicate need to test for underlying immunodeficiency (eg, <i>Serratia</i> spp)
Rare causes	
<i>Yersinia enterocolitica</i> *	Suppurative lymphadenitis; fever; diarrhea
Anthrax	Contact with infected animals or animal products; cuts or abrasions; begins as painless, often pruritic papule that rapidly enlarges and develops a central vesicle or bulla, followed by a painless ulcer

* Infection can persist and become more chronic in appearance.

¶ Often associated with generalized lymphadenopathy.

Graphic 97718 Version 3.0

Antimicrobial regimens for children with acute unilateral cervical lymphadenitis

Antimicrobial therapy	Dose*	Spectrum	Comments
Oral therapy			
Amoxicillin-clavulanate [¶] 125 mg/5 mL suspension 250 mg/5 mL suspension 250 mg tablet ^Δ 500 mg tablet	40 mg/kg per day orally divided every 8 hours (maximum 1.5 g/day)	MSSA GAS Oral anaerobes	Anaerobic coverage indicated for associated periodontal disease or poor dental hygiene
Amoxicillin-clavulanate [¶] 200 mg/5 mL suspension 400 mg/5 mL suspension 200 mg chewable tablet 400 mg chewable tablet	25 to 45 mg/kg per day orally divided every 12 hours (maximum 1.75 g/day)	MSSA GAS Oral anaerobes	Anaerobic coverage indicated for associated periodontal disease or poor dental hygiene
Cefadroxil	30 mg/kg per day orally divided every 12 hours (maximum 2 g/day)	MSSA GAS	
Cephalexin	25 to 100 mg/kg per day orally divided every 6 or 8 hours (maximum 4 g/day)	MSSA GAS	
Clindamycin [◇]	30 mg/kg per day orally divided every 6 or 8 hours (maximum 1.8 g/day)	MSSA [◇] CA-MRSA [◇] GAS Oral anaerobes	Anaerobic coverage indicated for associated periodontal disease or poor dental hygiene Oral suspension may be unpalatable, affecting adherence
Trimethoprim- sulfamethoxazole [§] (TMP- SMX, cotrimoxazole)	10 mg/kg per day orally divided every 12 hours (maximum 320 mg/day)	MSSA CA-MRSA <i>Bartonella henselae</i>	Not active against GAS, so should not be used for empiric therapy
Parenteral therapy			
Ampicillin-sulbactam [¶]	100 to 200 mg/kg per day IV divided every 6 hours (maximum 8 g/day of ampicillin component)	MSSA GAS Oral anaerobes Gram-negative organisms	Anaerobic coverage indicated for associated periodontal disease or poor dental hygiene
Cefazolin	50 to 100 mg/kg per day IV divided every 8 hours (maximum dose 6 g/day)	MSSA GAS	
Clindamycin [◇]	40 mg/kg per day IV divided every 6 or 8 hours (maximum 2.7 g/day)	MSSA [◇] CA-MRSA [◇] GAS Oral anaerobes	Anaerobic coverage indicated for associated periodontal disease or poor dental hygiene Preferred in communities with low [◇] prevalence of clindamycin-resistant <i>S.</i> <i>aureus</i>
Linezolid	<12 years: 30 mg/kg per day IV divided every 8 hours (maximum 1.8 g/day) ≥12 years: 20 mg/kg per day IV divided every 12 hours (maximum 1.2 g/day)	MSSA CA-MRSA GAS	
Nafcillin	150 to 200 mg/kg per day IV divided every 4 or 6 hours (maximum dose 12 g/day)	MSSA GAS	

Oxacillin	150 to 200 mg/kg per day IV divided every 4 or 6 hours (maximum dose 12 g/day)	MSSA GAS	
Piperacillin-tazobactam [¥]	300 mg/kg per day IV divided every 6 or 8 hours (maximum dose 16 g/day of piperacillin component)	MSSA GAS Oral anaerobes Gram-negative organisms	Anaerobic coverage indicated for associated periodontal disease or poor dental hygiene
Vancomycin	45 to 60 [‡] mg/kg per day IV divided every 6 or 8 hours (maximum 4 g/day)	MSSA CA-MRSA GAS	Preferred in communities with substantial [◇] prevalence of clindamycin-resistant <i>S. aureus</i>

MSSA: methicillin-susceptible *Staphylococcus aureus*; GAS: group A *Streptococcus*; CA-MRSA: community-associated methicillin-resistant *S. aureus*; IV: intravenously.

* The doses recommended above are intended for patients with normal renal function; the doses of some of these agents must be adjusted in patients with renal insufficiency.

¶ Dosed according to the amoxicillin or ampicillin component.

Δ This tablet is only for children who weigh ≥40 kg.

◇ The prevalence of clindamycin-resistant *S. aureus* varies geographically and may be more than 10 percent in some communities. The threshold prevalence of clindamycin-resistant *S. aureus* for choosing vancomycin varies from center to center, usually ranging from 10 to 25 percent, trying to balance the benefit of definitive therapy for the patient with the risk of increasing vancomycin resistance in the community.

§ Dosed according to the trimethoprim component.

¥ Dosed according to the piperacillin component.

‡ 60 mg/kg per day is recommended for children with serious infections (eg, toxic-appearing, fluctuant nodes, concomitant cellulitis).

Adjustment of dose and frequency may be necessary based upon serum concentration monitoring.

Graphic 97715 Version 2.0

Infectious causes of subacute/chronic unilateral cervical lymphadenitis in children

Infectious agent	Clinical features
Common causes	
Nontuberculous mycobacteria	Usually occurs in children <5 years; frequent involvement of submandibular and tonsillar nodes; nontender; gradual enlargement with fluctuance, violaceous discoloration, and development of sinus tract; lack of response to antistaphylococcal and antistreptococcal antibiotics; TST may show 5 to 15 mm of induration at 48 hours; negative interferon-gamma release assay*
Cat scratch disease	Cat exposure; papule at site of inoculation (not always present); possible conjunctivitis; positive <i>Bartonella henselae</i> serology
Uncommon causes	
Toxoplasmosis¶	Exposure to cat feces; ingestion of poorly cooked meat, soil, or contaminated food; posterior cervical involvement
<i>Mycobacterium tuberculosis</i> ¶	Birth in, travel to, or contact with a visitor from a region endemic for <i>M. tuberculosis</i> ; TST usually with ≥15 mm induration at 48 hours; positive interferon-gamma release assay
<i>Mycobacterium bovis</i>	Ingestion of unpasteurized dairy products; exposure to cattle
Cervicofacial actinomycosis	Slowly progressive nontender indurated mass that evolves into multiple abscesses, fistulae, and draining sinus tracts
Rare causes	
<i>Nocardia brasiliensis</i>	Cutaneous lesions
Aspergillosis	Trauma, including burns and surgical wounds
Sporotrichosis	Papule at site of inoculation that usually ulcerates but may remain nodular with overlying erythema; similar lesions along lymphatic channels ("sporotrichoid spread")

TST: tuberculin skin test.

* With rare exception (eg, *Mycobacterium kansasii*, *Mycobacterium marinum*, *Mycobacterium szulgai*, *Mycobacterium goodii*).

¶ Often associated with generalized lymphadenopathy.

Graphic 97720 Version 3.0

Infectious causes of subacute/chronic bilateral cervical lymphadenitis in children

Infection	Clinical features
Common causes	
Epstein-Barr virus (EBV)*	Infectious mononucleosis (fever, exudative pharyngitis, hepatosplenomegaly); positive monospot or EBV serology
Cytomegalovirus (CMV)*	Mononucleosis-like illness; positive CMV serology
Uncommon causes	
Human immunodeficiency virus (HIV)*	High-risk behavior (unprotected sexual contact, injection drug use, etc)
Toxoplasmosis*	Exposure to cat feces; ingestion of poorly cooked meat, soil, or contaminated food; posterior cervical involvement
<i>Mycobacterium tuberculosis</i> *	Birth in, travel to, or contact with a visitor from a region endemic for <i>Mycobacterium tuberculosis</i> ; tuberculin skin test usually with ≥ 15 mm induration at 48 hours; positive interferon-gamma release assay
<i>Mycobacterium bovis</i>	Ingestion of unpasteurized dairy products; exposure to cattle
Syphilis*	High-risk sexual behavior
Rare causes	
Brucellosis*	Travel to or living in endemic area; ingestion of unpasteurized dairy products
Histoplasmosis*	Associated skin lesions

* Often associated with generalized lymphadenopathy.

Graphic 97719 Version 4.0

***Mycobacterium avium* adenitis**



M. avium cervical lymphadenitis in the parotid and submandibular regions. The parotid node underwent incomplete excision and began to relapse. The submandibular node began to spontaneously drain and formed an overlying scab.

Graphic 69475 Version 4.0

Contributor Disclosures

C Mary Healy, MD Nothing to disclose **Jan E Drutz, MD** Nothing to disclose **Glenn C Isaacson, MD, FAAP** Nothing to disclose **Morven S Edwards, MD** Grant/Research/Clinical Trial Support: Pfizer [Group B Streptococcus]. **Mary M Torchia, MD** Grant/Research/Clinical Trial Support: Pfizer [Group B Streptococcus].

Contributor disclosures are reviewed for conflicts of interest by the editorial group. When found, these are addressed by vetting through a multi-level review process, and through requirements for references to be provided to support the content. Appropriately referenced content is required of all authors and must conform to UpToDate standards of evidence.

[Conflict of interest policy.](#)