

Neonatal Cholestasis

Frederick J. Suchy, MD*

Objectives After completing this article, readers should be able to:

1. Know when cholestatic liver disease should be excluded in the diagnosis of the infant who has jaundice.
2. Describe the importance of early recognition and diagnostic evaluation of the infant who has cholestasis.
3. Characterize the most difficult problem in evaluating the infant who has cholestasis.
4. Discuss the restoration of bile flow in infants who have biliary atresia.
5. Know the conditions to which malabsorption in infants who have cholestasis can lead.

Introduction

Cholestatic jaundice is a typical presenting feature of neonatal liver disease rather than a late manifestation, as often observed in the older child or adult. This relates, in part, to an immaturity of hepatic excretory function, sometimes referred to as “physiologic cholestasis” of the newborn. The number of distinct disorders presenting with cholestasis may be greater in the neonatal period than at any other time of life. Cholestasis occurs frequently because of susceptibility to infection during the perinatal period, the initial effects of congenital malformations, particularly of the biliary tree, and the presentation of genetic and metabolic disorders. Table 1 shows the more common disorders that can present with cholestatic jaundice. In the neonate, the clinical and laboratory features of the many disorders manifesting cholestasis are similar. It is important for the pediatrician to differentiate the more infrequent occurrence of cholestatic jaundice from common unconjugated hyperbilirubinemia. Once cholestatic liver disease has been established, prompt referral to a pediatric gastroenterologist is required to define a specific diagnosis and, if possible, initiate therapy or manage complications of liver disease.

The overall incidence of neonatal liver disease manifesting clinical or biochemical evidence of cholestasis is approximately 1 in 2,500 live births. Idiopathic neonatal hepatitis, an anachronistic term, has been reported to have an incidence of 1 in 4,800 to 9,000 live births. However, reliable figures do not exist regarding the current incidence because newer and more accurate diagnostic methods have decreased markedly the number of infants previously labeled as having idiopathic neonatal hepatitis. The incidence of biliary atresia ranges from 1 in 8,000 to 21,000 live births according to reports from several centers around the world. The Figure shows an estimate of the relative frequency of the most important disorders producing cholestatic liver disease. Extrahepatic biliary atresia is the most common disease and consistently has accounted for one third of all cases in multiple reports over several decades. Various forms of inherited cholestasis may occur in 10% to 20% of cases. Approximately 10% are caused by α_1 -antitrypsin deficiency. Other inborn errors of metabolism comprise about 20% of all cases. Congenital infections, including those caused by so-called “TORCH agents,” account for about 5% of cases. In contrast to reports as late as 10 years ago, in which idiopathic neonatal hepatitis accounted for almost one third of the cases, improved diagnostic methods has decreased this category to no more than 10% to 15% of cholestatic infants.

Early recognition of neonatal cholestasis is essential for effective treatment of metabolic or infectious liver diseases. The surgical management of biliary anomalies, including choledochal cysts and biliary atresia, requires timely recognition and diagnosis. Even when treatment is not yet available or effective, infants who have progressive liver disease benefit

*Professor and Chair, Department of Pediatrics, Mount Sinai School of Medicine, New York, NY.

Table 1. Most Frequent Causes of Neonatal Cholestasis

Obstructive Cholestasis

- Biliary atresia
- Choledochal cysts
- Bile duct paucity
- Neonatal sclerosing cholangitis
- Inspissated bile syndrome
- Gallstones/biliary sludge
- Cystic fibrosis
- Caroli disease

Intrahepatic Cholestasis

- Viral infection
 - Herpes simplex
 - Cytomegalovirus
 - Human immunodeficiency virus
 - Parvovirus B19
 - Other
- Bacterial infection
 - Sepsis
 - Urinary tract infection
 - Syphilis
- Genetic/metabolic disorders
 - Alpha₁-antitrypsin deficiency
 - Tyrosinemia
 - Galactosemia
 - Progressive familial intrahepatic cholestasis
 - Alagille syndrome
 - Other
- Endocrine disorders
 - Hypothyroidism
 - Hypopituitarism
- Toxic
 - Drugs
 - Parenteral nutrition
- Systemic
 - Shock
 - Heart failure
 - Neonatal lupus

from optimal nutrition support and medical management of the complications of cholestasis and possibly cirrhosis.

Delayed referral of infants who have neonatal cholestasis remains a significant problem. Because of early hospital discharge, inadequate follow-up of jaundiced neonates is common. Cholestatic jaundice sometimes is misdiagnosed as the hyperbilirubinemia associated with breastfeeding. An important point for the practitioner is that any infant who has jaundice at more than 14 days of age should have a fractionated serum bilirubin determination performed to exclude cholestasis as a cause of jaundice.

Clinical Features

Infants usually present with jaundice that may be continuous with neonatal hyperbilirubinemia or associated with an initial clearing of neonatal jaundice. The infant may have dark urine associated with the excretion of bile pigments. The stools may appear light-colored or completely devoid of pigment (acholic). Bleeding due to the coagulopathy of vitamin K deficiency or liver failure may occur. Infants whose cholestasis is caused by bacterial sepsis, hypopituitarism, or metabolic disorders such as galactosemia may be acutely ill. Infants who have metabolic liver disease may have poor feeding, inadequate weight gain, hypoglycemia, and hypotonia.

Several clinical features occur more commonly with biliary atresia, including female gender, normal birth-weight, earlier onset of jaundice and acholic stools, and the presence of an enlarged liver that has a firm or hard consistency. However, no details in the history or physical examination are capable of differentiating all infants who have intrahepatic cholestasis from those who have biliary atresia. Many infants who have intrahepatic cholestasis (10% to 15%) have cholestasis so severe that they have clinical, laboratory, and imaging findings that suggest biliary obstruction. The clinician also may be confused by the evolving nature of biliary atresia in which stools initially are pigmented and the physiologic hyperbilirubinemia initially clears in some infants.

Physical examination of the cholestatic infant may reveal hepatomegaly or hepatosplenomegaly. The patient should be examined carefully for dysmorphic facial features and other congenital anomalies, as occur in infants who have Alagille syndrome or other chromosomal defects. Infants who have congenital infection may have significant liver disease as well as microcephaly, growth restriction, or bleeding from thrombocytopenia.

Evaluation of the Cholestatic Infant

A systematic, consistent approach to the evaluation of the cholestatic infant is outlined in Table 2. The most important initial test is measurement of the serum conjugated bilirubin concentration to establish the presence of cholestasis. The conjugated fraction of serum bilirubin should be no higher than 15% of the total serum bilirubin concentration. Baseline assessment of the severity of liver dysfunction also is essential. However, standard liver biochemical test results are elevated variably and are nonspecific. Poor hepatic synthetic function at birth, including hypoglycemia and coagulopathy that is not corrected by administration of vitamin K, may reflect an inborn error of metabolism or an intrauterine infection that led to liver cell necrosis. Because hepatocyte mass in

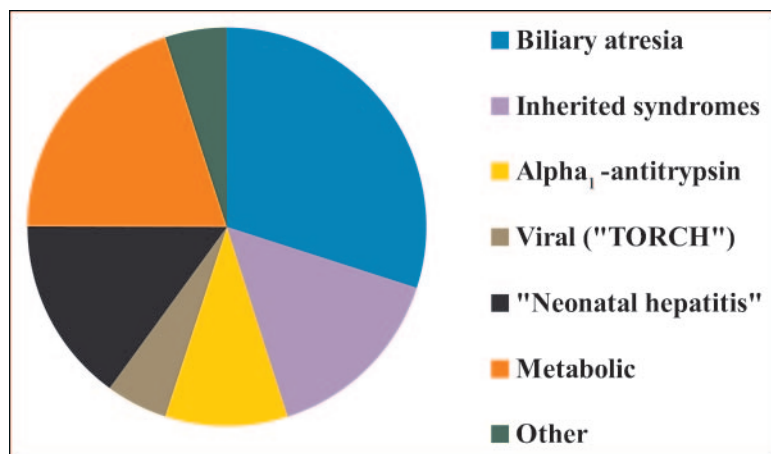


Figure. Estimated incidence of important disorders producing cholestatic liver disease.

some metabolic disorders is lost by apoptosis rather than cell necrosis, serum aminotransferase concentrations may be increased only modestly. The serum gamma glutamyl transferase activity may be of differential value in that paradoxically low or normal levels are found in the serum of some patients who have progressive familial intrahepatic cholestasis and with some inborn errors of bile acid metabolism. Bacterial cultures of blood, urine, and other fluids should be obtained, as dictated by the clinical picture. Viral serologies and cultures should be obtained if congenital infection is suspected. The results of neonatal screening tests for hypothyroidism and galactosemia should be obtained because these conditions require urgent therapy. A number of investigations are warranted to establish a specific diagnosis. However, the evaluation should be well structured to obtain only those tests that are indicated by the history and clinical findings (Table 2).

Ultrasonography is a particularly useful initial imaging modality for obtaining information about liver structure, size, and composition. This examination can be used to define the presence and size of the gallbladder, detect obstructing gallstones and sludge in the biliary tree, demonstrate ascites, and define cystic or obstructive dilatation of the biliary system. Extrahepatic anomalies also may be detected. Unfortunately, common bile duct dilatation is not a feature of biliary atresia. The common bile duct and gallbladder in this condition may not be visible or only a portion of the duct may be seen with a small gallbladder. A triangular echogenic density representing a triangular fibrous mass of tissue at the porta hepatis may be demonstrated on ultrasonography and is believed to be a specific finding for biliary atresia. Hepa-

tobiliary scanning using technetium-labeled imino-diacetic derivatives often is used to view the biliary tract. Infants who have biliary atresia do not excrete isotope into the gut, making the test 100% sensitive for this disorder. Unfortunately, specificity is not satisfactory in that isotope is not excreted in many infants who have intrahepatic cholestasis, particularly if there is a paucity of intrahepatic bile ducts, and with various forms of neonatal hepatitis.

Magnetic resonance cholangiography (MRC) is being performed more frequently in cholestatic infants. The instrumentation and software have improved significantly to allow the imaging of a normal biliary tree in infants. In several small studies, patent extrahepatic bile ducts and a gallbladder could

not be demonstrated in infants who had biliary atresia. Further studies are required before MRC evaluation of the cholestatic infant can be considered reliable.

Percutaneous liver biopsy represents the single most important diagnostic test in the evaluation of the cholestatic infant. In several studies, biliary atresia was diagnosed in 90% to 95% of cases. Characteristic findings on liver biopsy suggesting common duct obstruction include bile ductular proliferation, bile plugs in small bile ducts, and portal tract fibrosis and edema. The liver biopsy also may demonstrate hepatitis, viral inclusions characteristic of cytomegalovirus or herpes simplex virus infection, and changes suggesting a metabolic or storage disease.

When the clinical laboratory and histologic features of cholestatic liver disease suggest biliary atresia, the patency of the biliary tree should be examined directly at the time of the minilaparotomy and intraoperative cholangiography.

Biliary Atresia

Biliary atresia is the most common specific disorder causing cholestasis during the first weeks after birth. It is characterized by the complete obstruction of bile flow due to destruction or absence of all or a portion of the extrahepatic bile ducts. It is the most frequent cause of death from liver disease and referral for liver transplantation in children (approximately 50% of all cases).

Jaundice typically develops at 3 to 6 weeks of age in an otherwise well-appearing, thriving infant. In an uncommon, so-called embryonic form of biliary atresia, cholestatic jaundice may be present from birth. Approximately 10% to 15% of infants have other congenital malforma-

Table 2. Evaluation of the Infant Who Has Cholestasis

Initial Investigations

(Establish the presence of cholestasis, define severity of liver dysfunction, and detect readily treatable disorders)

- Fractionated serum bilirubin concentration
- Serum liver chemistries: alanine aminotransferase, aspartate aminotransferase, alkaline phosphatase, gamma glutamyl transferase
- Tests of liver function: serum glucose, albumin, cholesterol, ammonia, and coagulation studies (prothrombin time, partial thromboplastin time, coagulation factor levels)
- Complete blood count
- Bacterial cultures of blood, urine, other as indicated
- Paracentesis if ascites (examine for bile and infection)

Investigations to Establish a Specific Diagnosis

- Ultrasonography of liver and biliary system (magnetic resonance cholangiography in selected cases)
- Serum alpha₁-antitrypsin level and phenotype
- Serologies and cultures for viruses (TORCH agents, parovirus B19, human herpesvirus type 6, human immunodeficiency virus, other)
- Sweat chloride analysis
- Metabolic screen (urine and serum amino and organic acids)
- Endocrine studies (thyroxine, thyroid-stimulating hormone, evaluation for hypopituitarism as indicated)
- Urine and serum bile acid analysis
- Specific enzyme assays on liver tissue, fibroblasts, others such as red blood cells (eg, red cell galactose-1-phosphate uridylyltransferase activity)
- Hepatobiliary scintigraphy in selected cases (eg, assess for bile duct perforation)
- Percutaneous liver biopsy (routine histology, immunohistochemistry, viral culture and nucleic acid assays, electron microscopy, enzymology as required)
- Genetic testing as indicated
 - Cystic fibrosis
 - Alagille syndrome
 - Three forms of progressive familial intrahepatic cholestasis
- Exploratory laparotomy and intraoperative cholangiography if biliary obstruction not excluded

Modified from Suchy FJ. Approach to the infant with cholestasis. In: Suchy FJ, Sokol RJ, Balistreri WF, eds. *Liver Disease in Children*. Philadelphia, Pa: Lippincott, Williams & Wilkins; 2001:191

tions, including polysplenia, malrotation, preduodenal portal vein, and cardiovascular anomalies. There appears to be no genetic predisposition, and familial cases are extremely rare.

In most cases, biliary atresia is an evolving process, with progressive inflammatory and fibrotic obliteration of the extrahepatic biliary tree. During the evolution of biliary obstruction, the histopathology of the extrahepatic biliary tree may demonstrate varying degeneration of epithelial cells, inflammation, and fibrosis in periductal tissues. Bile ducts within the liver that extend to the porta hepatis usually are patent during the first postnatal weeks, but are destroyed progressively, probably by the

same process that leads to destruction of the extrahepatic bile ducts. Histopathologic findings on liver biopsy are consistent with large duct obstruction, including portal tract edema, bile ductular proliferation, and the presence of bile plugs in bile ductules.

The cause of biliary atresia remains unknown. Because of the inflammatory nature of the destructive process in the extrahepatic bile ducts, infection long has been considered a likely cause. A number of viruses over the years have been associated with but not proven to cause biliary atresia, including cytomegalovirus, rubella virus, and rotavirus. The role of these agents in causing the disorder remains uncertain. More recently, reovirus type 3 has received considerable attention. Reovirus RNA has been detected in the liver tissue of approximately 50% of patients who had biliary atresia and almost 80% of patients who had choledochal cysts. Immaturity of the immune system and genetic factors may contribute to the pathogenesis of the disorder. It is clear that in most cases, biliary atresia is not a true birth defect. However, in the 10% to 15% of cases that involve multiple congenital anomalies, injury to the biliary tract may begin prenatally and present with biliary obstruction at birth.

The diagnosis of biliary atresia involves the exclusion of other known causes of neonatal cholestasis (Table 2). Abdominal ultrasonography is particularly useful in the initial evaluation to exclude a choledochal cyst as a cause of obstruction. Liver biopsy remains the single most useful test in differentiating intrahepatic cholestasis from biliary obstruction. If the diagnosis of biliary atresia cannot be excluded by initial diagnostic tests, operative exploration and intraoperative cholangiography should be performed.

For patients found to have biliary atresia, the intraoperative cholangiogram should be followed by a biliary drainage procedure or the so-called hepatopuertoenterostomy operation developed by Kasai. This procedure con-

sists of transecting the fibrous tissue at the area of the porta hepatis, with subsequent apposition of a Roux-en-Y loop of intestine to act as a conduit for biliary drainage. The resection at the area of the porta hepatis may expose small but patent bile ducts that can be used to restore the bile flow. The rate of success in establishing bile flow is related directly to the age of the patient at the time of surgery. Bile drainage is achieved in more than 80% of infants operated on at younger than 60 days of age but in fewer than 20% of patients older than 90 days. Some patients who have biliary atresia may have patent proximal portions of the biliary tree or cystic structures in the porta hepatis that allow a conventional anastomosis with a segment of intestine, but these cases account for only 5% of affected infants.

The prognosis for untreated biliary atresia is extremely poor, with most patients dying from liver failure by 2 years of age. The Kasai procedure, although not curative in most patients, prolongs survival significantly. The 10-year actuarial rate for patients who have their native livers is approximately 30% in reports from multiple centers. Thus, children who have biliary atresia derive long-term benefit from the hepatic portoenterostomy procedure, although most have some persistent liver dysfunction and eventually may require liver transplantation. In a recent large series of patients from France, the overall 10-year survival rate of infants treated with the Kasai operation and, if necessary, liver transplantation was 72%.

Alpha₁-antitrypsin Deficiency

Alpha₁-antitrypsin deficiency may present with neonatal cholestasis and can be associated with progressive liver disease. Alpha₁-antitrypsin is the principal serum inhibitor of proteolytic enzymes, including neutrophil elastase. Patients who have the homologous deficiency state or the protease inhibitor ZZ phenotype (PiZZ) have markedly reduced amounts of alpha₁-antitrypsin, generally in the range of 10% to 15% of normal values. The incidence of the PiZZ phenotype is approximately 1 in 2,000 live births. Cholestatic jaundice occurs in approximately 10% to 15% of infants who have the PiZZ phenotype, and hepatomegaly and acholic stools may be present. Approximately 40% to 50% of infants who have the PiZZ phenotype are asymptomatic, but they may have abnormal liver biochemical test results in the first postnatal months.

On liver biopsy, a giant cell hepatitis may be present. Bile ductular proliferation is common, and paucity of the intralobular bile ducts may be found later. Periodic acid-Schiff-positive diastase-resistant inclusions accumulate

within hepatocytes and represent the abnormal alpha₁-antitrypsin protein. The accumulation of this material is responsible for producing liver injury.

It is unclear why only 10% to 15% of those who have the homologous deficiency state manifest liver disease. The outcome of neonatal cholestasis relating to alpha₁-antitrypsin deficiency varies. Although patients may develop cirrhosis in the first postnatal months, jaundice clears in most patients by 4 months of age. Abnormal findings on liver biochemical tests may persist and lead to cirrhosis later in life. There is no specific treatment for alpha₁-antitrypsin deficiency. Liver transplantation is curative for those progressing to cirrhosis.

Alagille Syndrome

Alagille syndrome is the most common form of familial intrahepatic cholestasis. Its features include chronic cholestatic liver disease and a variety of other congenital malformations. In addition to liver disease, patients often have congenital heart disease, with peripheral pulmonic stenosis being the most common defect. Patients also have dysmorphic facies and may have anomalies of the vertebrae, eyes, and kidneys. Short stature is frequent. Alagille syndrome is inherited as an autosomal dominant trait with variable penetrance and expressivity.

Cholestatic liver disease in Alagille syndrome is related to the paucity of interlobular bile ducts. Bile ducts are formed normally, but they are lost progressively with age by a mechanism that has not been defined. The onset of cholestasis often occurs in the neonatal period, with jaundice and acholic stools. In contrast to biliary atresia, liver size initially is normal or only slightly enlarged. Dysmorphic facial features may be difficult to recognize at birth, but they become more apparent by 2 years of age. Patients often develop intense pruritus by 6 months of age. Marked hyperlipidemia may produce severe cutaneous xanthomas during the first postnatal years.

Mutations in the *Jagged 1* gene are found in patients who have Alagille syndrome. This gene encodes one of several ligands for the notch receptor system that is involved in control of cell differentiation and proliferation.

The outcome in Alagille syndrome is guarded because of the progressive loss of bile ducts and the complications of severe cholestasis, including growth failure, metabolic bone disease, intractable pruritus, and xanthomas. In a recent series of 163 patients, actuarial survival with the native liver at 10 years was 51%. This figure increased to 68% with liver transplantation. The ability to undergo liver transplantation may be limited by severe congenital heart disease.

Table 3. Forms of Progressive Familial Intrahepatic Cholestasis (PFIC)

	PFIC1	PFIC2	PFIC3
Genetics	Autosomal recessive	Autosomal recessive	Autosomal recessive
Serum gamma-glutamyl transferase	Low	Low	High
Bile	Low bile acids	Low bile acids	Low phospholipids
Gene	<i>FIC1</i>	<i>BSEP</i>	<i>MDR3</i>
Gene product	P-type ATPase (function unknown)	Bile salt pump	Phospholipid transporter (membrane flippase)
Cell localization	Apical: gut, bile duct cells, canalicular membrane	Canalicular membrane	Canalicular membrane
Clinical course	Neonatal onset, variable progression	Neonatal onset, rapid progression	Neonatal or later onset with cholestasis, variable progression
Pruritus	++++	++++	±
Histology	Pseudoacinar pattern of hepatocytes, canalicular cholestasis, coarsely granular bile in bile canaliculi on electron microscopy	Giant cell transformation of hepatocytes, amorphous or dense bile in bile canaliculi on electron microscopy	Portal fibrosis, bile ductular proliferation

Cholestasis Associated With Parenteral Nutrition

Infants, particularly those born preterm, may develop cholestasis as a metabolic complication of total parenteral nutrition (TPN). The incidence of TPN-associated cholestasis is correlated inversely with birthweight, with the complication occurring in almost 50% of infants whose birthweights are less than 1,000 g. It also is related to the duration of therapy, with the onset often seen after 2 weeks of receiving TPN. Cholestasis occurs particularly in infants who have complicated medical courses, including those affected by respiratory distress, hypoxia, acidosis, necrotizing enterocolitis, sepsis, and short bowel syndrome.

The pathogenesis of TPN-associated cholestasis is multifactorial. Affected infants usually are of low birthweight and, because of a variety of other medical problems, often are not fed enterally and may have significant gastrointestinal problems, including short bowel syndrome and bacterial overgrowth. The parenteral nutrition solutions have improved significantly over the years and have much less toxicity if used appropriately. However, intravenous lipid emulsions and their phytosterol content may play a role in producing liver dysfunction. Among critically ill infants, a number of hepatotoxins may be synergistic in producing oxidative liver injury, including bacterial endotoxin, lipid emulsions, specific amino acids and degradation products, and trace elements such as copper, aluminum, and manganese.

TPN-associated cholestasis has the potential to lead to progressive liver disease and cirrhosis. It is extremely important to initiate enteral feedings as early as possible to provide a stimulus for bile flow, gallbladder contraction, and intestinal motility. Even small amounts of enteral nutrition that may not be significant nutritionally may have positive effects on hepatobiliary function. For cholestatic patients who require continued TPN, the manganese and copper content of the solution should be reduced or eliminated because these metals may accumulate to toxic levels and contribute to liver injury. The fat-soluble vitamin status of the patient should be monitored closely, and the TPN infusate adjusted accordingly. After TPN is discontinued and total enteral feeding established, cholestasis may not resolve completely for many months. The infant may have residual hepatic fibrosis or even cirrhosis.

Progressive Familial Intrahepatic Cholestasis (PFIC)

These inherited forms of cholestasis of hepatocellular origin often present in the neonate or during the first year after birth. The intra- and extrahepatic biliary tree is normal. Three distinct forms have been identified (Table 3). Mutations in transporters that contribute to bile formation have been defined in the three forms. A diagnosis of PFIC1 or PFIC2 should be considered in cholestatic infants who have paradoxically normal or low serum levels of gamma-glutamyl transferase.

Table 4. Fat-soluble Vitamin Supplementation in Chronic Cholestasis

Vitamin	Deficiency	Treatment/Prevention
Vitamin A	Xerophthalmia, keratomalacia, night blindness	5,000 to 25,000 U/d of water-miscible preparation
Vitamin D	Rickets, osteomalacia	Drisdol 3 to 10 times recommended dietary allowance for age or 1,25(OH) ₂ D 0.05 to 0.3 mcg/kg per day
Vitamin E	Progressive neuromuscular degeneration (truncal and limb ataxia, depressed vibratory and position sensation, peripheral neuropathy, proximal muscle weakness, ophthalmoplegia)	d-alpha tocopheryl polyethylene glycol-1000-succinate 15 to 25 IU/kg per day
Vitamin K	Coagulopathy	Phytonadione 2.5 to 5 mg twice weekly up to 5 mg/d; phytonadione injection 2 to 5 mg intramuscularly every 4 wk

PFIC can progress to cirrhosis. Patients, particularly those who have PFIC1 and 2, often develop intractable pruritus from the disorder. Biliary diversion has been used as an effective treatment for pruritus, and there is some evidence that liver disease improves after this procedure. Liver transplantation is required for patients who progress to cirrhosis.

Medical Management of Chronic Cholestasis

For the infant who has cholestatic liver disease, efforts should be directed toward promoting growth and development and minimizing discomfort relating to the complications of cholestasis. Protein-energy malnutrition leading to growth failure is a frequent consequence of chronic cholestatic liver disease, occurring in about 60% of affected patients. Steatorrhea is common in children who have cholestasis. Decreased bile acid excretion results in impaired intraluminal lipolysis, solubilization, and intestinal absorption of long-chain triglycerides. Because of steatorrhea and increased energy expenditure, caloric intake should be approximately 125% of the recommended dietary allowance based on ideal body weight. Many patients have a significant deficit in weight and require additional calories for catch-up growth. Oral feeding is the preferred route, but anorexia and decreased muscle mass due to progressive liver disease may require continuous or supplemental nocturnal nasogastric feedings to provide sufficient calories to reverse malnutrition. Medium-chain triglycerides do not require solubilization by bile salts before intestinal absorption and, thus, can provide needed calories when administered orally in one of several infant formulas or as an oil supplement. For infants progressing to end-stage liver disease and facing liver transplantation, the outcome is improved when there is no malnourishment.

Adequate protein intake (2.0 to 3.0 g/kg per day in infants) also must be delivered and usually is tolerated

well without hyperammonemia unless liver failure is advanced. The casein hydrolysates present in the medium-chain triglyceride-containing formulas are satisfactory. Amounts up to 4.0 g/kg per day may be provided to correct malnutrition prior to liver transplantation, but such administration requires careful biochemical monitoring.

Cholestatic infants also are at significant risk of developing fat-soluble vitamin deficiency, which should be prevented by adequate administration of oral supplements. A recent advance has been the use of water-soluble esters of fat-soluble vitamins, which are available commercially in preparations for infants. The polyethylene glycol-1000-succinate (TPGS) forms can be absorbed directly into the enterocyte without incorporation into micelles. Liquid preparations of the water-soluble ester of vitamin E TPGS are available for treatment of older patients. The absorption of standard doses of other fat-soluble vitamins may be facilitated when administered with TPGS vitamin E. The manifestations of fat-soluble vitamin deficiencies and the approach to their prevention and treatment are outlined in Table 4.

Pruritus caused by chronic cholestasis can cause considerable morbidity and often develops by 3 months of age. The antibiotic rifampicin, probably acting through stimulation of pathways for metabolism of hydrophobic bile acids and other pruritogenic compounds, may provide relief in some patients when administered in a dose of 10 mg/kg per day. Bile acid-binding agents such as cholestyramine may be efficacious, but they are difficult to administer, particularly to infants. They also can be associated with increased steatorrhea and have the potential to produce intestinal obstruction. Phenobarbital is used occasionally but should be avoided because of behavioral changes and drowsiness. Ursodeoxycholic acid, a hydrophilic bile acid, may be useful when administered

in doses of 10 to 20 mg/kg per day. It is used to stimulate bile flow and displace toxic bile acids from the liver, but has the potential to produce diarrhea and may be hepatotoxic in patients who have poor bile flow.

Several different biliary diversion procedures have been used successfully to relieve intractable pruritus and xanthomas in patients who have severe intrahepatic cholestasis. It is believed that the procedures improve the cholestatic process by removing hydrophobic bile acids and other toxic compounds that produce liver injury and lead to pruritus.

Conclusion

Cholestatic jaundice defined as conjugated hyperbilirubinemia is a typical presenting feature of neonatal liver disease and often is confused with the more common prolonged unconjugated hyperbilirubinemia sometimes seen with breastfeeding. The pediatrician is essential for detecting liver disease through a careful history, physical examination, and fractionation of the serum bilirubin. Biliary atresia is the most common disorder producing cholestasis during the first postnatal months. Liver dysfunction from biliary obstruction must be differentiated from numerous intrahepatic disorders, such as congenital

infection and inborn errors of metabolism. Early recognition and a stepwise diagnostic evaluation of the cholestatic infant are essential in successfully treating or managing the complications of the many metabolic and infectious liver diseases of the infant as well as surgically relieving obstruction in patients who have biliary atresia.

Suggested Reading

- Balistreri WF. Inborn errors of bile acid biosynthesis and transport. Novel forms of metabolic liver disease. *Gastroenterol Clin North Am.* 1999;28:145–172
- Fischler B, Papadogiannakis N, Nemeth A. Aetiological factors in neonatal cholestasis. *Acta Paediatr.* 2001;90:88–92
- Jacquemin E. Progressive familial intrahepatic cholestasis. *J Gastroenterol Hepatol.* 1999;14:594–599
- Karpen SJ. Update on the etiologies and management of neonatal cholestasis. *Clin Perinatol.* 2002;29:159–180
- Lykavieris P, Hadchouel M, Chardot C, Bernard O. Outcome of liver disease in children with Alagille syndrome: a study of 163 patients. *Gut.* 2001;49:431–435
- Sokol RJ, Mack C. Etiopathogenesis of biliary atresia. *Semin Liver Dis.* 2001;21:517–524
- Suchy FJ. Approach to the infant with cholestasis. In: Suchy FJ, Sokol RJ, Balistreri WB, eds. *Liver Disease in Children*. 2nd ed. Philadelphia, Pa: Lippincott, Williams & Wilkins; 2001: 187–194

PIR Quiz

Quiz also available online at www.pedsinreview.org.

10. A 3-week-old girl is brought to your office for evaluation of jaundice. She was born after an uncomplicated term gestation and normal vaginal delivery. The mother's blood group is B Rh-positive and the baby's is O Rh-negative. The infant has been breastfed and has gained 400 g since birth. She was noted to be jaundiced from the second postnatal day, with her bilirubin peaking at 13 mg/dL (222.3 μ mol/L) on the fifth day. The mother reports that the baby has remained jaundiced, and her stools are looking much lighter than before. Physical examination reveals a normal-appearing newborn except for jaundice. Laboratory evaluation shows: hemoglobin, 13 g/dL (130 g/L) and bilirubin, 8.9 mg/dL (152.2 μ mol/L), with a direct fraction of 6.1 mg/dL (104.3 μ mol/L). Which of the following conditions could best explain these findings?
- A. Alagille syndrome.
 - B. Extrahepatic biliary atresia.
 - C. Human milk jaundice.
 - D. Maternal-fetal blood group incompatibility.
 - E. Prolonged physiologic jaundice.
11. A 9-month-old boy presents with failure to thrive since 1 month of age. The mother has noticed that he has been jaundiced for the last 2 months. The infant was born after an uncomplicated pregnancy and delivery. His birthweight was 3.1 kg, and he now weighs 6.2 kg. Physical examination reveals dysmorphic facies, with a broad forehead, widely spaced eyes, and a small mandible. Mild icterus is present. A grade 3/6 systolic murmur is heard over the pulmonic area. The liver edge is firm and 2 cm below the right costal margin. Radiologic examination reveals a normal heart size and fusion defects of several thoracic vertebrae. Laboratory examination documents a serum bilirubin of 6.8 mg/dL (116.3 μ mol/L), with a direct fraction of 5.1 mg/dL (87.2 μ mol/L). Which of the following conditions best explains these findings?
- A. Alagille syndrome.
 - B. Alpha₁-antitrypsin deficiency.
 - C. Choledocal cyst.
 - D. Extrahepatic biliary atresia.
 - E. Progressive familial intrahepatic cholestasis.
12. You are caring for a 6-month-old boy who is diagnosed with progressive familial intrahepatic cholestasis (PFIC1). Physical examination reveals the liver to be firm and palpable 3 cm below the costal margin. His serum bilirubin is 8.5 mg/dL (145.4 μ mol/L), with a direct fraction of 6.7 mg/dL (114.6 μ mol/L). Deficiency of which of the following nutrients is he most susceptible to?
- A. Ascorbic acid.
 - B. Copper.
 - C. Niacin.
 - D. Thiamine.
 - E. Vitamin E.
13. A 3-week-old girl is brought to your office for evaluation of jaundice. She was born after a normal term pregnancy. The mother's blood group is O Rh-positive, and the baby's is B Rh-negative. The baby was noted to be jaundiced on the second postnatal day, but the condition seemed to improve over the next week. The infant has been breastfed and gaining weight satisfactorily. Over the last week, the mother has noticed that the baby is becoming jaundiced again. Physical examination reveals a normal-appearing newborn except for yellowish discoloration of the sclerae and skin. Laboratory examination shows: hemoglobin, 13 g/dL (130 g/L) and bilirubin, 8.9 mg/dL (152.2 μ mol/L), with a direct fraction of 6.1 mg/dL (104.3 μ mol/L). Which of the following is the next most appropriate step in evaluation?
- A. Abdominal ultrasonography.
 - B. Direct and indirect Coombs test.
 - C. Exploratory laparotomy and intraoperative cholangiography.
 - D. Liver biopsy.
 - E. Serology for congenital infections (TORCH).