



ISMJ



Mission Statement
Editorial Board
Submit an Article
Back Issues

International SportMed Journal for FIMS

[Journal Home](#)

[SportMed Update](#)

[Dietary
Supplements](#)

[Rehab Notes](#)

[Position Statements](#)

[Physician Forum
Other Services](#)

[SportMed Store](#)

[FIMS Home](#)

[Site Search:](#)

[Power Search](#)

[About eSportMed](#)
[Contact Us](#)
[Help](#)
[Site Map](#)
[eSportMed Home](#)



Powered by **Human
Kinetics**

ISMJ, 1(1), March 2000, Copyright © 2000

Pathophysiology of Chronic Groin Pain in the Athlete

Authors: [John Orchard](#), [John W Read](#), [Geoffrey M Verrall](#), [John P Slavotinek](#)

Keywords

groin, pubalgia, hernia, adductor, athletic injuries\diagnosis

Abstract

Chronic groin pain is a common symptom in the football and hockey codes. Although there is a large differential diagnosis, this review focuses upon the peri-pubic causes of isolated groin pain (pubalgia). Publications that included a hypothesis of the cause of pubalgia were reviewed. The competing views were that pubalgia arises from a single pathology, multiple unrelated pathologies, and multiple interdependent pathologies. An interdependent model is the most practical, in the absence of scientific proof for either paradigm. Posterior inguinal canal deficiency is established as a common finding in male athletes, but it may be asymptomatic. Osteitis pubis and insertional adductor tendinopathy are also both common entities that often are considered to coexist. Overuse in sports involving kicking, sprinting, and changing direction is implicated as a cause of pubalgia by all paradigms. Various surgeries to the pubic region may achieve results by i) correcting a force imbalance at the pubic symphysis and surrounding pubic rami created by abnormal adductor and abdominal muscles; ii) reducing compartment pressures; and iii) enforcing a rest period and gradual resumption of activities.

Key Points

1. Groin pain arising from pubic structures (pubalgia) should be differentiated from referred pain.
2. Kicking, sprinting, and changing direction place the greatest load on the groin.
3. Overload of the bone-tendon insertions at the pubic symphysis may produce many coexisting abnormalities.
4. Pubalgia may be managed conservatively without extensive investigation.

Objective

Groin pain is one of the least understood and explained symptoms in

[Abstract Only](#)

[Key Points](#)

[Table of Contents for
Vol. 1, Iss. 1](#)

sports medicine, despite multiple efforts to study the cause, treat the condition, and review the subject. There is no consensus on diagnosis, pathophysiology, or management. Yet, in many sports, it is a common diagnostic and management challenge for the clinician. Injuries to the groin region are particularly common in the hockey [1-6] and football [7-20] codes.

The groin is a complex anatomical region, and the differential diagnosis of groin pain is correspondingly large. It is a junctional region where three major body areas (abdomen, pelvis, and lower limbs) meet. The groin includes the inguinal region of the lower abdominal wall, the pubic bone and its attachments, and the femoral triangle of the lower limbs. It would be convenient if we could divide patients along such lines at the time of presentation, but in clinical practice groin pain is often poorly localized and tends to overlap more than one region. For the purposes of this review, groin pain has been classified according to origin from either pubic or non-pubic structures (Table 1). There is generally good agreement regarding the medical diagnosis and management of pain arising from non-pubic structures (e.g., hip joint osteoarthritis). However, there is no such consensus regarding the significance of either the clinical or radiological (imaging) findings that pertain to athletes in whom groin pain appears to arise from pubic structures. Within this group, which is the subject of this paper, many different theories have been proposed. Within the discipline of musculoskeletal medicine, similar theories abound regarding the likely cause(s) of chronic lumbosacral pain [21]. The groin and low back share the features that their anatomy involves many layers, that most physical examination does not isolate single anatomical structures, and that there is a chasm between the teachings of clinical practice and established scientific fact.

Chronic groin pain may or may not be the only presenting complaint. If an associated symptom is present (e.g., lump, numbness, clicking, stiffness, dysuria), the diagnosis is often clear. However, the majority of patients with chronic groin pain have no concurrent associated symptoms and hence are usually more difficult to diagnose, as there is a large differential diagnosis for this symptom. The site of pain is usually poorly localized but is typically provoked by athletic activity (particularly sprinting, changing direction, and kicking) with temporary relief after rest. Groin pain often recurs if vigorous activity is resumed.

Pubalgia has been defined in terms of athletes with groin pain that have no obvious hernias and no other etiology for groin pain [22, 23]. In this paper we consider *pubalgia* as pain arising from local structures in the pubic region (Table 1). The differential diagnosis therefore includes adductor tendinopathy, osteitis pubis, sports (occult, incipient) hernias, and conjoint tendon lesions.

Table 1 Causes of Athletic Groin Pain

	Pubic	Non-pubic
Musculotendinous	Adductor tendinopathy	Iliopsoas tendinopathy
	Inguinal canal pathology	Rectus femoris tendinopathy
	Conjoint tendinopathy	Various muscle strains
	Rectus abdominus tendinopathy	

Bone	Osteitis pubis	Pelvic stress fractures
Joint	Pubic instability	Hip joint pathology
		Lumbar spine pathology
		Sacroiliac joint pathology
Nerve entrapment	Ilioinguinal nerve	
	Obturator nerve	
Genitourinary		Prostatitis
		Epididymitis
		Salpingitis

The physical examination features of pubalgia can be tenderness on or adjacent to the pubic symphysis and pain on contraction of the abdominal, hip flexor, and adductor muscles. Pain and tenderness at the external inguinal ring and/or the impression of a cough impulse on palpation at the external inguinal ring may be associated with pubalgia, but a macroscopically visible lump suggests a specific diagnosis of inguinal hernia. Hip joint range of motion should be assessed as part of the examination of a groin injury. Decreased range of the short adductors (measured in supine, with hip and knee flexion to allow the soles of the feet to touch each other [24]) may be a feature of an adductor injury. Decreased range of hip internal rotation has been associated with osteitis pubis [25]. Substantial and/or global reduction of hip range of motion suggests a diagnosis of hip joint pathology.

We aim to review the topic of chronic athletic groin pain arising from pubic and/or peri-pubic structures, focusing on the proposed theories for development of pain and the implications that these theories have for diagnosis and management. The majority of objective evidence to support these theories is radiological. Thus, this review will include a review of radiological findings of the pubic region.

Data Sources

The databases used for searches were [MEDLINE](#) and [SPORTDiscus](#) from the years 1980-1999. The search strategy was to look for any of a number of keywords related to groin injuries (groin OR adductor OR hernia or osteitis pubis), combined with a filter limiting the search to sports injuries [Medline: AND (athletic injury OR sports), SPORTDiscus: AND injury]. In addition, a small number of references were included from the personal libraries of the authors for review, including some historical references published prior to 1980.

Selection Process

Chronic groin pain generally has not been subjected to well designed scientific trials. Most of the studies published regarding this area would be discarded for the purposes of meta-analysis using minimal scientific criteria. Hence, the purpose of this review was to be inclusive rather than exclusive, to summarize those theories that have been published, albeit based primarily on conjecture. Both original and review papers were considered and selected based on whether they described a theory, deduction, or speculation as to the proposed pathophysiology of chronic groin pain in athletes. No evidenced-based criteria were used to exclude published studies.

Data Extraction

Studies were categorized according to the following:

1. Those authors who assert that the majority of pubalgia is caused by a single entity and directs treatment to this single cause for most cases;
2. Those authors who assert that there are many distinct causes of pubalgia and that they must be clinically differentiated and treated differently;
3. Those authors who support a complex interdependent model that involves multiple pathologies that usually coexist and result in a common clinical presentation, and that usually require similar common management.

The objective evidence to support or reject each of these theories was very limited. Most of the objective evidence consists of radiological findings. There is also some published evidence regarding clinical examination findings and outcome results of uncontrolled surgical case series, but this evidence is limited. The theories were assessed based on their explanation of the various objective findings that have been published in association with pubalgia.

Results

Theories on Groin Pain

Single Common Diagnosis Paradigm

The "Sports" Hernia. The most common single diagnosis reported was the "sports" hernia or a related condition of the posterior wall of the inguinal canal or inferomedial abdominal wall. Most studies consisted of surgical series of case reports. Rates of post-operative symptom resolution and return to competitive sport ranged from 63-97% [6, 16, 19, 23, 26-33]. Preoperative diagnosis was made by either clinical examination and/or herniography ([Figure 3](#)), and surgical management was a variation of inguinal canal herniorraphy.

Studies regarding the sports hernia differ in their description of pathology and their method of diagnosis. Some authors felt that a sports hernia (disruption of the inguinal canal that did not produce a visible herniation) could be detected on physical examination (palpation) either consistently or occasionally [6, 13, 29, 32-34]. Other authors did not believe that physical examination could detect a sports hernia [3, 14, 16, 19, 27, 28, 31, 35-38]. Despite this disagreement, none of those authors who believe that a sports hernia can be palpated clinically have published reliability data for this examination finding.

Herniography ([Figure 3](#)) is considered useful and accurate by some authors [19, 26, 27, 29, 34, 37-40] but not others [9, 16, 33, 36]. Soft tissue diagnostic ultrasound has recently been recommended as providing similar information to herniography using a non-invasive technique [14, 41]. Abnormal findings in both herniography [26, 27, 37, 38, 40] and ultrasound [14] are reported to correlate with groin pain. Both these investigations will often exhibit a bilateral abnormality when the pain is only unilateral. Ultrasound findings in asymptomatic footballers are sometimes abnormal, although it has been shown to occur less often than for players with groin pain [14].

Although there is some disagreement, the most common pathological finding at surgery for the sports hernia is a bulge of the posterior wall of the inguinal canal that occurs medial to the inferior epigastric artery (usually at the superficial ring). Anatomists have found this abnormality to exist in a very high proportion (>25%) of the adult population [39, 41-44], most of whom do not complain of pain with a clinical hernia. Although abnormalities of the conjoint tendon have been reported at surgery, one study that took biopsies from this area found no histopathological abnormality [45].

The scientific inadequacies of published literature regarding the sports hernia has led to one review suggesting that a sports hernia does not constitute a credible explanation for chronic groin pain in athletes [46]. This was on the basis that there was no difference in the perioperative findings in cured and non-cured athletes, that many athletes had similar findings on their opposite asymptomatic side, and further clinical investigation of non-cured, operated athletes gave an alternative and treatable diagnosis in 80% of cases. Fredberg and Kissmeyer-Neilsen's [46] arguments may be used to reject the concept of the sports hernia as a diagnosis that occurs in isolation. However, numerous authors have demonstrated the posterior wall of the inguinal canal deficiency both surgically and with two imaging modalities. This pathology is associated with pubalgia, although the temporal relationship between the two is not clear.

Adductor Tendinopathy. Insertional tendinopathy (tendinosis, tendinitis) has been reported to occur at over 30 sites in the body, including the adductor insertion at the symphysis pubis [47]. The acceptance of *insertitis* or *enthesopathy* as a common diagnosis at sites of major tendon insertion is not questioned. However, even for tendons in which the diagnosis of tendinopathy is common and not difficult, such as the patellar tendon, the pathophysiology is poorly understood [48]. Insertional tendinopathy of the patellar tendon has a poorer prognosis than tendinopathy of the main body of the tendon [49]. Other sites of tendinosis, such as the lateral epicondyle of the elbow, may serve as a model for the management of adductor tendinosis [50].

Those authors who believe that adductor tendinopathy is the most common diagnosis in cases of chronic groin pain usually identify that other diagnoses often coexist [51-55]. The plain X-ray and bone scan imaging features of osteitis pubis have been considered to be diagnostic criteria for insertional adductor tendinopathy [56].

The specific diagnosis of adductor tendinopathy can be used to justify adductor tenotomy as a form of management. The described methods of tenotomy vary [52, 54, 57, 58]. One study of adductor tenotomy resulted in a significant post-operative strength deficit in the adductors of the operated side [58]. This did not result in any functional or sporting limitation in the patients studied. However, for athletes for whom speed may be critical, further study is required to assess whether a strength deficit of adduction may result in decreased maximal sprinting speed. A recent anatomical study has shown that the adductor longus tendon is much longer anteriorly than posteriorly [59], explaining that a low adductor tenotomy can be performed that releases the most anterior fibers of adductor longus while keeping the majority of the musculotendinous unit intact. This method may eliminate or minimize loss of adduction strength after the procedure.

Osteitis Pubis. Osteitis pubis has well defined radiographic features that include sclerosis, symphysis narrowing, irregularity, and cystic change on X-ray (Figure 1) [60, 61]. These findings may be absent in early or milder forms of the disease [54]. Increased tracer uptake in the delayed phase of a bone scan (Figure 2) has been shown useful for the diagnosis of osteitis pubis but not for prognosis [54]. MRI imaging has recently been used for

the diagnosis of pubalgia (Figures 9-12) [62, 63], with a recent study showing a high correlation between parasymphyseal bone marrow edema and chronic groin pain, which suggests that the bone may be the primary source of pain in pubalgia [64].

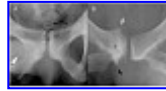


Figure 1. Osteitis pubis. Plain X-ray findings in 2 separate cases:

A. Irregular resorption of articular cortex and variable mild subcortical sclerosis is seen along both sides of the symphysis. Also note subtle soft tissue calcification in the line of the right adductor longus (white arrowhead), indicative of simultaneous pathological change at two separate anatomical structures in this case.

B. Longstanding disease on the right side has produced prominent traction spurs at the pubic insertion of rectus abdominis (white arrow) and adductor origin (black arrow), a broad zone of bony enthesial sclerosis at the conjoint tendon insertion and adductor origin (*), and irregular resorption of articular cortex along the right side of the pubic symphysis.

(Courtesy of: Atlas of Imaging in Sports Medicine, McGraw-Hill, Sydney 1998)

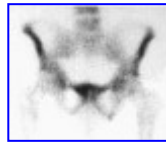


Figure 2. Osteitis pubis. Isotope bone scan in this case shows an asymmetric pattern of increased tracer uptake that corresponds in distribution with the insertions of the right conjoint, adductor longus, and rectus abdominis tendons. Such changes support the view that multiple separate but closely related anatomical structures often contribute to the clinical syndrome of pubalgia.

Authors who propose that osteitis pubis is a common cause of groin pain usually also identify a large differential diagnosis or possible coexisting pathologies [61, 65-67]. Osteitis pubis has been associated with sacroiliac degeneration [68, 69], limitations in hip joint movement [25, 61], and fatigue fracture involving the bony origin of the gracilis muscle on the pelvis [70].

Although ostectomy is considered for long-standing refractory cases with large degenerative cysts [67], most authors recommend conservative treatment for osteitis pubis but caution that this may take 6-9 months to resolve the symptoms [54, 58].

Differential Diagnosis Paradigm

Many authors advise that there is a large differential diagnosis that should be entertained for pubalgia, with the correct differentiation made to ensure optimal management [13, 20, 55, 71-77]. The findings that have been recommended for distinguishing between conditions include:

1. Location of tenderness to differentiate between soft tissue/fascial causes and bone/joint causes.
2. Pain on contraction with different muscle groups to differentiate between the various structures that could be stressed from such a maneuver.
3. Imaging findings (Figures 1-12).

These methods for differential diagnosis are very logical. However, in practice many cases are positive for multiple pathologies. Three studies that systematically diagnosed various conditions according to set criteria found multiple diagnoses coexisting in 27% [13], 45% [72], and 95% of

subjects [78]. The latter study, although examining the smallest group of patients ($N = 21$), was the only one that used multiple examiners blinded to each other's findings.

Given that there is already a long list of non-pubic causes of groin pain, advocating a large differential diagnosis within the subset of pubalgia leads to impractical complexity. Reviews of groin pain commonly list 20-30 differential diagnoses that must be considered [20, 52, 74, 76].

Multiple Diagnoses Coexisting

Many authors (see below) describe concurrent findings or recommend management that considers coexisting pathological processes.

Some authors recommend that the posterior wall of the inguinal canal be repaired as treatment, even in cases where osteitis pubis is considered an active diagnosis [16, 29, 34, 35, 79, 80]. Others recommend combined herniography and adductor tenotomy [57], or adductor and abdominal tenotomy [54, 71].

As the deficiency of the posterior wall of the inguinal canal is often bilateral (when pain is only unilateral) and can occur in asymptomatic patients, it has been suggested that this pathology may be either a precursor to, or consequence of, other groin pathology [14]. A recent study of the nerves of the inguinal canal has found considerable variation of the anatomy [81]. This study suggested that nerve entrapment might be the cause of pain in the sports hernia. It also may help explain why some cases of deficiency of the posterior wall of the inguinal canal are asymptomatic.

Recent studies have described a new diagnosis of obturator nerve entrapment [82, 83]. Sensory deficit of the obturator nerve was sometimes, but not always, present in the cases described. Many subjects diagnosed as having a primary pathology of obturator nerve entrapment had positive bone scan results, suggesting coexisting diagnoses. The findings in these cases are somewhat analogous to anterior compartment syndrome of the shin, in which linear increased uptake on bone scan is common, and patients may or may not have symptoms of superficial peroneal nerve entrapment.

Enthesopathy of the pubic insertion of the inguinal ligament has been proposed as a common cause of groin pain (coexisting with other diagnoses in many cases) [84]. The pubic insertions of the inguinal ligament (external oblique), other abdominal muscles, and the adductor muscles are very closely related. Enthesopathy of the inguinal ligament appears to be a speculative diagnosis when suggested by a single author, but it is equally difficult to see how enthesopathy of any of the specific tendon insertions can be isolated on clinical examination alone.

Corticosteroid injections have been suggested as a treatment for osteitis pubis [85]. This form of management infers that a tenoperiosteal component exists as part of the pathology for osteitis pubis ([Figure 7](#)), as a pure bony stress lesion would not be expected to respond well to corticosteroids.

An interdependent model can be created to explain the pathogenesis of athletic pubalgia as a bone and/or tendon overload resulting from:

1. Overuse (in the activities of kicking, sprinting, and changing direction);
2. Force imbalance at the symphysis pubis and surrounding pubic bone resulting from weakened (or torn) abdominal muscles and/or inflexible (or weakened) adductor muscles;
3. Positive feedback from secondary phenomena, such as chronic

inflammation, calcification, herniation, increased compartment pressure, and nerve entrapments, all of which may create greater muscle dysfunction.

Investigations

Investigations may include X-ray, isotope bone scan, ultrasound (US), CT, MRI, EMG, and contrast herniography. In general, investigations of the groin region exhibit a high degree of apparently abnormal findings, although the relevance of some of this "pathology" is questionable. For research purposes, US and MRI are the tests best suited for screening of asymptomatic athletes and routine follow-up of subjects, as they are non-radiating and non-invasive. For clinical assessment of children and young adults, US and MRI may be preferred to avoid exposure to radiation of the gonads.

X-ray is a useful investigation, as it is cheap, readily available, and useful at excluding important non-pubic causes of groin pain (including advanced stress fractures, unexpected bone tumors, and hip and S/I joint pathology) and may often show signs of chronic osteitis pubis ([Figure 1](#)).

Isotope bone scan is a sensitive method of detecting pelvic and femoral stress fractures and a good indicator of current disease activity in cases of osteitis pubis ([Figure 2](#)).

Intraperitoneal contrast radiography (or herniography) ([Figure 3](#)) has been used to demonstrate inguinal hernias in patients with chronic groin pain. The test is an invasive procedure that carries a risk of complications [86].

Ultrasound can demonstrate a number of structures ([Figures 4, 5](#)) in the pubic region [55, 87]. Dynamic real-time ultrasound has been reported recently as an aid in the diagnosis of *indirect* inguinal hernia in nonathletes [41, 88-90] and is further suggested as an aid to the diagnosis of *incipient direct* inguinal hernia in athletes [14] ([Figure 6](#)). Like contrast herniography, ultrasound can show hernia lesions but does not necessarily predict clinical relevance. US is the only imaging modality capable of demonstrating the dynamic function of the inguinal canal in real-time, but it is very dependent on the skill of the operator.



Figure 3. Direct inguinal hernia. Contrast herniogram in this case shows an asymmetric bulge (arrow) of the left posterior inguinal wall.



Figure 4. Pubic insertitis or enthesopathy. Transverse ultrasound scan of the symphysis pubis shows a swollen left conjoint tendon insertion (arrowhead) and irregular resorption or "pitting" of cortex at the associated anterior aspect of left pubic bone (arrow) by comparison with the normal opposite side. These changes correspond in distribution with the pattern of abnormal tracer uptake seen on isotope bone scanning and are consistent with the sonographic features of chronic tendinopathy seen at other body sites.

(Courtesy of: *Atlas of Imaging in Sports Medicine*, McGraw-Hill, Sydney 1998)

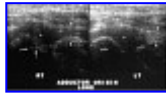


Figure 5. Chronic right adductor origin tendinopathy. Comparative longitudinal ultrasound scans of both adductor longus tendons (arrowheads) have been obtained. On the right side there is relative swelling at the tendon origin (asterisks) and irregular resorption or "pitting" at the associated pubic bone cortex (arrow). Symptomatic lesions have some degree of associated tenderness on direct probing with the transducer (tendonitis), even if only very mild. However, similar changes can also occur in asymptomatic individuals or in athletes who have groin pain but show no tenderness on probing with the transducer (tendonosis).

(Courtesy of: *Atlas of Imaging in Sports Medicine*, McGraw-Hill, Sydney 1998)

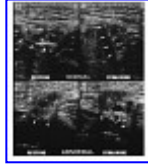


Figure 6. Still ultrasound images of posterior inguinal canal deficiency (views: normal and abnormal comparing resting and straining).

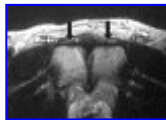


Figure 7. MRI case of Osteitis pubis. Axial T1-weighted fast-spin echo image of the symphysis pubis shows mild intratendon signal hyperintensity (arrows) at both conjoint tendon insertions. Note that the distribution of the disease process in this case centers upon tendon rather than joint.

(Courtesy of: *Am J Sports Med.* 1995;23:601-606)

Many of the pathological changes on imaging tests such as plain X-ray, isotope bone scanning, and ultrasound involve the pubic entheses (Figures 1-7). The underlying radiologic-pathologic features are very similar to those found in "chronic insertional tendinopathy" at other anatomical locations [91].

The CT scan can demonstrate the chronic bone changes of osteitis pubis, pelvic or femoral stress fracture, hip joint OA, and is sensitive to soft tissue calcification.

The MRI scan provides excellent overall soft tissue and bone information (Figures 7-11) but is insensitive for soft tissue calcification and is not able to assess incipient hernia pathology. The significance and use of MRI scanning in athletic pubalgia has not yet been established and therefore, because of its cost, is difficult to recommend as an initial investigation for injured athletes, with the possible exception of professional athletes.

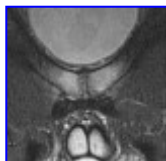

Figure 8. MRI appearance of osteitis pubis; T2Fat-suppressed Coronal view. Increased signal intensity of the pubic bone marrow extending from the pubic body bilaterally into both superior pubic rami.

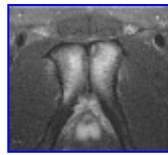


Figure 9. MRI appearance of osteitis pubis; T2 Fat-suppressed Axial view. Same patient as Figure 8. Note the view is axial to the pubic body. Increased signal intensity of the pubic bone marrow of the pubic body.

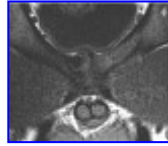


Figure 10. MRI appearance of osteitis pubis; T1 Coronal view. Irregular pubic symphysis and Superior "beaking" consistent with osteophyte/ligament hypertrophy. Decreased signal intensity of the left parasymphyseal area consistent with cyst formation.

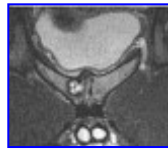

Figure 11. MRI appearance of osteitis pubis; T2 Fat-suppressed Coronal view. Same patient as Figure 10. Increased signal intensity of the pubic bone marrow extending into the superior pubic rami bilaterally. Large cyst of the left parasymphyseal area corresponding to the T1 image.

Conclusions

Imaging, surgical and clinical studies, and theory all provide substantial evidence that insertional adductor tendinopathy, osteitis pubis, and deficiency of the posterior inguinal canal wall exist as pathological entities. The studies are very inconclusive as to what relative contribution each of these entities makes to the symptom of pubalgia in clinical sports medicine.

A "single-diagnosis" paradigm that attempts to explain the majority of pubalgia with one diagnosis is ignorant of the other coexisting pathology that is commonly present.

One of the major tenets of traditional allopathic medicine is that an accurate anatomical diagnosis must be made prior to formulating a management plan. This approach, which is generally very successful within clinical medicine, gives rise to the "differential diagnosis" paradigm of pubalgia. Unfortunately, this paradigm gives rise to unnecessary complexity, over-investigation, and confusion in the area of chronic groin pain. Clinical examination often appears to be insensitive to the different pathologies involved in pubalgia. To fully document all of the possible pathological changes that may be exhibited in pubalgia, a limited use of plain X-ray, bone scan, CT scan, MRI scan, and dynamic ultrasound would be required. This would clearly be over-investigation for the average patient.

Our conclusion from the literature review is that a "multiple pathology" paradigm of pubalgia, focusing on overload at the bone-tendon complex is the most appropriate approach. This gives rise to a functional approach to chronic groin pain, similar to the approach that has become more popular

for chronic lumbar spine pain. In chronic spinal pain, the first objective is to exclude major diagnoses based on "red flag" symptoms and signs [92], then to manage remaining "mechanical" pain in a functional sense. In chronic groin pain, we recommend first differentiating pubalgia from non-pubic causes of groin pain (using history, physical examination and "basic" investigations, such as plain X-ray and bone scan). If the pain has been isolated to the pubic region, other pathological processes (insertional tendinopathy, bony overload, and weakness of the posterior wall of the inguinal canal) can be presumed as likely to be present and coexisting. A more specific diagnosis than pubalgia may not be necessary before embarking upon a course of conservative management, which will be the recommended management in a majority of cases.

Surgical management has a role to play in cases of failed conservative treatment of chronic groin pain. Various surgeries to the pubic region may achieve results by (1) correcting a force imbalance at the pubic symphysis created by abnormal adductor and abdominal muscles; (2) reducing compartment pressures; and (3) enforcing a rest period and the gradual resumption of activities. The two most common categories of surgical procedure are the repair of the posterior inguinal canal wall (usually herniorrhaphy) and limited adductor tenotomy. These may be performed as individual procedures or in conjunction with one another.

In the past, the specialty of the consulting surgeon (e.g., general vs. orthopedic) has too often dictated surgical management. We recommend that a subspecialty group of surgeons be developed with training in, at least, general surgery and orthopedics who can treat multiple pathologies in the groin and be unbiased in their assessment.

We also support further research in this area, particularly the inclusion of reliability studies and control groups. Although we do not currently recommend their routine use in clinical practice, ultrasound and MRI are generally the best tools for research, as they will allow comparison with asymptomatic controls and follow-up imaging to be performed without risk to subjects.

References

1. Biasca N, Simmen HP, Bartolozzi AR, Trentz O. Review of typical ice hockey injuries. Survey of the North American NHL and Hockey Canada versus European leagues. *Unfallchirurg*. 1995;98(5):283-288.
2. Emery CA, Meeuwisse WH, Powell JW. Groin and abdominal strain injuries in the National Hockey League. *Clin J Sport Med*. 1999; 9(3):151-156.
3. Lacroix VJ, Kinnear DG, Mulder DS, Brown RA. Lower abdominal pain syndrome in national hockey league players: a report of 11 cases. *Clin J Sport Med*. 1998;8(1):5-9.
4. Merrifield HH, Cowan RF. Groin strain injuries in ice hockey. *J Sports Med*. 1973;1(2):41-42.
5. Renstrom P. Swedish research in sports traumatology. *Clin Orthop*. 1984;(191):144-158.
6. Simonet WT, Saylor HL III, Sim L. Abdominal wall muscle tears in hockey players. *Int J Sports Med*. 1995;16(2):126-128.
7. Crisp T. Football injuries: a new season begins. *Practitioner*. 1997;241(1577):440-442, 444.
8. Culpepper MI, Niemann KM. High school football injuries in Birmingham, Alabama. *South Med J*. 1983;76(7):873-875, 878.

9. Ekstrand J, Hilding J. The incidence and differential diagnosis of acute groin injuries in male soccer players. *Scand J Med Sci Sports*. 1999;9(2):98-103.
10. Gibbs N. Injuries in professional rugby league. A three-year prospective study of the South Sydney Professional Rugby League Football Club. *Am J Sports Med*. 1993;21(5):696-700.
11. Gibbs N. Common rugby league injuries. Recommendations for treatment and preventative measures. *Sports Med*. 1994;18(6):438-450.
12. Ingoldby CJ. Laparoscopic and conventional repair of groin disruption in sportsmen [see comments]. *Br J Surg*. 1997;84(2):213-215.
13. Lovell G. The diagnosis of chronic groin pain in athletes: a review of 189 cases. *Aust J Sci Med Sport*. 1995;27(3):76-79.
14. Orchard JW, Read JW, Neophyton J, Garlick D. Groin pain associated with ultrasound finding of inguinal canal posterior wall deficiency in Australian Rules footballers. *Br J Sports Med*. 1998;32(2):134-139.
15. Orchard J, Wood T, Seward H, Broad A. Comparison of injuries in elite senior and junior Australian football. *J Sci Med Sport*. 1998;1(2):82-88.
16. Polglase AL, Frydman GM, Farmer KC. Inguinal surgery for debilitating chronic groin pain in athletes. *Med J Aust*. 1991;155(10):674-677.
17. Seward HG, Patrick J. A three year survey of Victorian Football League injuries. *Aust J Sci Med Sport*. 1992;24(2):51-54.
18. Seward H, Orchard J, Hazard H, Collinson D. Football Injuries in Australia at the elite level. *Med J Aust*. 1993;159:298-301.
19. Yilmazlar T, Kizil A, Zorluoglu A, Ozguc H. The value of herniography in football players with obscure groin pain. *Acta Chir Belg*. 1996;96(3):115-118.
20. Zimmerman G. Groin pain in athletes. *Aust Fam Physician*. 1988;17(12):1046-1052.
21. Bogduk N. The causes of low back pain [editorial]. *Med J Aust*. 1992;156:151-153.
22. Brunet B, Brunet-Geudj E, Genety J. La pubalgie syndrome "fourretout" pour une plus grande rigueur diagnostique et therapeutique. *Intanes Medicaux*. 1984;55:25-30.
23. Taylor DC, Meyers WC, Moylan JA, Lohnes J, Bassett FH, Garrett WE Jr. Abdominal musculature abnormalities as a cause of groin pain in athletes. Inguinal hernias and pubalgia. *Am J Sports Med*. 1991;19(3):239-242.
24. Harvey D, Mansfield C, Grant M. *Screening Test Protocols. Pre-Participation Screening of Athletes*. Canberra, Australia: Australian Sports Commission; 1998:76.
25. Williams J. Limitation of hip joint movement as a factor in traumatic osteitis pubis. *Br J Sports Med*. 1978;12:129-133.
26. Ekberg O, Blomquist P, Olsson S. Positive contrast herniography in adult patients with obscure groin pain. *Surgery*. 1981;89:532-535.
27. Smedberg SG, Broome AE, Gullmo A, Roos H. Herniography in athletes with groin pain. *Am J Surg*. 1985;149(3):378-382.
28. Malycha P, Lovell G. Inguinal surgery in athletes with chronic groin pain: the "sportsman's" hernia. *Aust N Z J Surg*. 1992;62(2):123-125.
29. Hackney RG. The sports hernia: a cause of chronic groin pain. *Br J Sports Med*. 1993;27(1):58-62.
30. Evans DS. Sports hernia: the diagnosis and laparoscopic management. *Sports Exerc Inj*. 1998;4(1):28-31.

31. Williams P, Foster ME. "Gilmore's groin"-or is it? *Br J Sports Med*. 1995;29(3):206-208.
32. Urquart D, Packer G, McLatchie G. Return to sport and patient satisfaction levels after surgical treatment for groin disruption. *Sports Exerc Inj*. 1996;2:37-42.
33. Gilmore J. Groin Pain in the soccer athlete: fact, fiction, and treatment. *Clin Sports Med*. 1998;17(4):787-794.
34. Hackney RG. The sports hernia. *Sports Med Arthrosc Rev*. 1997;5(4):320-325.
35. Kemp S, Batt ME. The "sports hernia": a common cause of groin pain. *Physician Sportsmed*. 1998;26(1):36-38, 40, 42-44.
36. Eames N, Deans G, Lawson J, Irwin S. Herniography for occult hernia and groin pain. *Br J Surg*. 1994;81:1529-1530.
37. Smedberg S. Herniography and laparoscopic hernia surgery: developments in the diagnosis and treatment of hernias. *Sports Med Arthrosc Rev*. 1997;5(4):313-319.
38. Badruddoja M, Bush I, Angres G, Ansari S, Schwartz M, Sullivan K. The role of herniography in undiagnosed groin pain. In: Arregui M, Nagan R., eds. *Inguinal Hernia. Advances or Controversies?* Oxford, UK: Radcliffe; 1994.
39. Gullmo A. Herniography. The diagnosis of hernia in the groin and incompetence of the pouch of Douglas and pelvic floor. *Acta Radiol Suppl*. 1980;361:1-76.
40. Gullmo A, Broome A, Smedberg S. Herniography. *Surg Clin North Am*. 1984;64(2):229-244.
41. Schumpelick V, Treutner K, Arlt G. Inguinal hernia repair in adults. *Lancet*. 1994;344:375-379.
42. Scott P. *External herniae*. In: Dudley H, Waxman B, eds. *An Aid to Clinical Surgery*. Edinburgh, UK: Churchill Livingstone; 1984:231.
43. Skandalakis J, Gray S, Skandalakis L. Surgical anatomy of the inguinal area. *World J Surg*. 1989;13:490-498.
44. Skandalakis J, Colborn G, Androulakis J, Skandalakis L, Pemberton L. Embryologic and anatomic basis of inguinal herniorrhaphy. *Surg Clin Nth Am*. 1993;73(4):799-836.
45. Lovell G, Malycha P, Pieterse S. Biopsy of the conjoint tendon in athletes with chronic groin pain. *Aust J Sci Med Sport*. 1990;22(4):102-103.
46. Fredberg U, Kissmeyer-Nielsen P. The sportsman's hernia-fact or fiction? *Scand J Med Sci Sports*. 1996;6(4):201-204.
47. Jozsa L, Kannus P. *Human Tendons*. Champaign, IL: Human Kinetics; 1997:212.
48. Khan K, Maffuli N, Coleman B, Cook J, Taunton J. Patellar tendinopathy: some aspects of basic science and clinical management. *Br J Sports Med*. 1998;32:346-355.
49. Testa V, Capasso G, Maffulli N, Bifulco G. Ultrasound-guided percutaneous longitudinal tenotomy for the management of patellar tendinopathy. *Med Sci Sports Exer*. 1999;31(11):1509-1515.
50. Kraushaar B, Nirschl R. Tendinosis of the elbow (tennis elbow). *J Bone Joint Surg*. 1999;81-A(2):259-278.
51. Renstrom P. Groin injuries: a true challenge in orthopaedic sports medicine. *Sports Med Arthrosc Rev*. 1997;5:247-251.
52. Jarvinen M, Orava S, Kujala U. Groin pain (Adductor Syndrome). *Oper Tech*

Sports Med. 1997;5(3):133-137.

53. Holmich P. Adductor-related groin pain in athletes. *Sports Med Arthrosc Rev.* 1997;5:285-291.

54. Martens MA, Hansen L, Mulier JC. Adductor tendinitis and musculus rectus abdominis tendopathy. *Am J Sports Med.* 1987;15(4):353-356.

55. Kalebo P, Karlsson J, Sward L, Peterson L. Ultrasonography of chronic tendon injuries in the groin. *Am J Sports Med.* 1992;20(6):634-639.

56. Holmich P, Uhrskou P, Ulnits L, Kanstrup IL, Nielsen MB, Bjerg AM, Krosgaard K. Effectiveness of active physical training as treatment for long-standing adductor-related groin pain in athletes: randomised trial. *Lancet.* 1999;353(9151):439-443.

57. Christel P, Djian P, Roger B, Witvoet J, Demarais Y. Apport de l'IRM dans la strategie du traitement chirurgical des pubalgies. (Benefit of MRI in the surgical strategy-process about groin pain.) *Journal de traumatologie du sport (Paris).* 1996;13(2):95-101.

58. Akermark C, Johansson C. Tenotomy of the adductor longus tendon in the treatment of chronic groin pain in athletes. *Am J Sports Med.* 1992;20(6):640-643.

59. Tuite DJ, Finegan PJ, Saliaris AP, Renstrom PA, Donne B, O'Brien M. Anatomy of the proximal musculotendinous junction of the adductor longus muscle. *Knee Surg Sports Traumatol Arthrosc.* 1998;6(2):134-137.

60. Coventry M, Mitchell W. Osteitis pubis: observations based on a study of 45 patients. *J Am Med Assoc.* 1961;178:898-905.

61. Fricker P, Taunton J, Ammann W. Osteitis pubis in athletes: infection, inflammation or injury? *Sports Med.* 1991;12(4):266-279.

62. Ekberg O, Sjoberg S, Westlin N. Sports-related groin pain: evaluation with MR imaging. *Eur Radiol.* 1996;6(1):52-55.

63. Ghebontni L, Roger B, Christel P, Rodineau J, Grenier P. Pubalgie du sportif: interet de l'IRM dans le demembrement des lesions. *Journal-de-traumatologie-du-sport.* 1996;13(2):86-93.

64. Verrall G. Osteitis pubis in Australian rules footballers: a stress injury to the pubic bone. In: *Aust Conf Sci Med Sport.* Adelaide, Australia: Sports Medicine Australia; 1998.

65. Fricker PA. Osteitis pubis. *Sports Med Arthrosc Rev.* 1997;5(4):305-312.

66. Ekberg O, Kesek P, Besjakov J. Herniography and magnetic resonance imaging in athletes with chronic groin pain. *Sports Med Arthrosc Rev.* 1997;5(4):274-279.

67. Zimmerman G, Young D, Toomey M. Osteitis pubis [abstract]. In: *Aust Conf Sci Med Sport.* Canberra, Australia: Sports Medicine Australia; 1996.

68. Major NM, Helms CA. Pelvic stress injuries: the relationship between osteitis pubis (symphysis pubis stress injury) and sacroiliac abnormalities in athletes. *Skeletal Radiol.* 1997;26(12):711-717.

69. La Ban M, Meerschaert J, Taylor R, Tabor H. Symphyseal and sacroiliac joint pain associated with pubic symphysis instability. *Arch Phys Med Rehab.* 1978;59(10):470-472.

70. Wiley JJ. Traumatic osteitis pubis: the gracilis syndrome. *Am J Sports Med.* 1983;11(5):360-363.

71. Karlsson J, Sward L, Kalebo P, Thomee R. Chronic groin injuries in athletes. Recommendations for treatment and rehabilitation. *Sports Med.* 1994;17(2):141-148.

72. Rochcongar P, Le Gall F, Jan J. La pubalgie du sportif: mise au point a

- propos d'une etude retrospective de 214 patients. (Pubic pain in athletes: a review and a retrospective study of 214 patients.) *Science & sports (Paris)*. 1996;11(3):135-139.
73. Renstrom P, Peterson L. Groin injuries in athletes. *Br J Sports Med*. 1980;14(1):30-36.
74. Ruane JJ, Rossi TA. When groin pain is more than "just a strain": navigating a broad differential. *Physician Sportsmed*. 1998;26(4):78-80, 87-89, 93-94, 97-100, 103.
75. Lynch SA, Renstrom PA. Groin injuries in sport: treatment strategies. *Sports Med*. 1999;28(2):137-144.
76. Fricker PA. Management of groin pain in athletes. *Br J Sports Med*. 1997;31(2):97-101.
77. Westlin N. Groin pain in athletes from Southern Sweden. *Sports Med Arthrosc Rev*. 1997;5(4):280-284.
78. Ekberg O, Persson NH, Abrahamsson PA, Westlin NE, Lilja B. Longstanding groin pain in athletes. A multidisciplinary approach. *Sports Med*. 1988;6(1):56-61.
79. Xethalis J, Lorei M. Soccer injuries. In: Nicholas HE, ed. *The Lower Extremity and Spine in Sports Medicine*. St. Louis, MO: Mosby; 1995:1509-1557.
80. Gullmo A. Herniography. *World J Surg*. 1989;13:560-568.
81. Akita K, Niga S, Yamato Y, Muneta T, Sato T. Anatomic basis of chronic groin pain with special reference to sports hernia. *Surg Radiol Anat*. 1999;21(1):1-5.
82. Bradshaw C, McCrory P, Bell S, Brukner P. Obturator nerve entrapment. A cause of groin pain in athletes. *Am J Sports Med*. 1997;25(3):402-408.
83. Brukner P, Bradshaw C, McCrory P. Obturator neuropathy: a cause of exercise-related groin pain. *Physician Sportsmed*. 1999;27(5):62-64, 67-68, 73.
84. Ashby E. Chronic obscure groin pain is commonly caused by enthesopathy: tennis elbow of the groin. *Br J Surg*. 1994;81(11):1632-1634.
85. Holt MA, Keene JS, Graf BK, Helwig DC. Treatment of osteitis pubis in athletes: results of corticosteroid. *Am J Sports Med*. 1995;23(5):601-606.
86. Ekberg O. Complications after herniography in adults. *Am J Radiol*. 1983;140:491-495.
87. Read J. *ATL Protocol Guide: Groin Ultrasound-Gross Anatomy and Ultrasound Findings*. Bothell, WA: ATL; 1998. On-line: .
88. Arregui M. The value of ultrasound in the diagnosis of hernias. In: Arregui M, Nagan, R, eds. *Inguinal Hernia. Advances or Controversies?* Oxford, UK: Radcliffe; 1994:73-79.
89. Truong S, Pfingsten F, Dreuw B, Schumpelick V. Value of sonography in diagnosis of uncertain lesions of the abdominal wall and inguinal region. *Chirurg*. 1993;64:468-475.
90. Lawrenz K, Hollman A, Carachi R, Cacciaguerra S. Ultrasound assessment of the contralateral groin in infants with unilateral inguinal hernia. *Clin Radiol*. 1994;49:546-548.
91. Anderson I, Read J, Steinweg J. *Atlas of Imaging in Sports Medicine*. Sydney, Australia: McGraw-Hill; 1998.
92. Bigos S, Davis G. Scientific application of sports medicine principles for acute low back problems. *J Orthop Sports Phys Ther*. 1996;24(4):192-207.

